Technical Bulletin 2021

PARASITES OF MITHUN (*Bos frontalis*): PREVENTION AND CONTROL MEASURES

Jayanta Kumar Chamuah | Biswa Ranjan Maharana | Vivek Joshi
Kamni Paia Biam | Sapunii Stephen Hanah | H. Lalzampuia | M.H Khan

ICAR-NATIONAL RESEARCH CENTRE ON MITHUN
MEDZIPHEMA, NAGALAND - 797 106
Website: www. nrcmithun.icar.gov.in
Nrc On Mithun NRCMITHUN Nrc Mithun

Technical Bulletin 2021

Parasites of Mithun (*Bos frontalis*): Prevention and Control Measures

Jayanta Kumar Chamuah, PhD
Scientist, Veterinary Parasitology
Animal Health Section

Biswa Ranjan Maharana, PhD
Scientist, Veterinary Parasitology
Regional Research Centre, LUVAS, Karnal

Vivek Joshi, PhD
Scientist, Veterinary Medicine
Animal Health Section

Kamni Paia Biam, MSc
Scientist, Agricultural Extension
Extension Section

Sapunii Stephen Hanah, PhD
Scientist, Livestock Production and Management
Livestock Production and Management Section

H. Lalzampuia, PhD
Scientist, Veterinary Microbiology
Animal Health Section

M. H. Khan, PhD
Principal Scientist, Animal Reproduction
Animal Physiology & Reproduction Section

भाकृअनुप ICAR

ICAR-NATIONAL RESEARCH CENTRE ON MITHUN
MEDZIPHEMA, NAGALAND – 797 106
Website: www. nrcmithun.icar.gov.in
Nrc On Mithun NRCMITHUN Nrc Mithun

I.C.A.R. N.R.C. MITHUN-NAGALAND

Technical Bulletin

Authors:
Jayanta Kumar Chamuah
Biswa Ranjan Maharana
Vivek Joshi
Kamni Paia Biam
Sapunii Stephen Hanah
H. Lalzampuia
M.H Khan

Published by:
Director, ICAR-NRC on Mithun, Medziphema, Nagaland

Published on July, 2021

Copy available at:
ICAR-NRC on Mithun, Medziphema, Nagaland-797106

Acknowledgement:
Authors are thankful to
Director, ICAR-National Research Centre on Mithun for kind logistic help.

Recommended Citation:
Chamuah, J. K., Maharana , B.R., Joshi, V., Biam, K.P., Hanah, S.S., Lalzampuia, H. and Khan, M.H. 2021. Parasites of Mithun (*Bos frontalis*): Prevention and Control Measures. Technical Bulletin, ICAR-National Research Centre on Mithun, Nagaland. https://nrcmithun.icar.gov.in.

Design and Printed by:
M/s. Royal Offset Printers, A-89/1, Naraina Industrial Area, Phase-I, New Delhi-110 028

PREFACE

The northeastern region of India is considered as the heaven of parasites due to the agro geo-climatic condition of this region. The congenial atmosphere in terms of relative humidity, soil PH, temperature, and rainfall are quite helpful for propagating the life cycle of different parasites. Besides this, peculiar topography along with unawareness about the predisposing factor can also aggravate the incidence of different diseases. Apart from the traditional livestock of this region, mithun husbandry also plays an important role in the livelihood of tribal people. This animal plays a very crucial role in the socioeconomic and cultural life of the tribal population. Mithun is considered to be a sign of superiority and prosperity among the tribal life of Arunachal Pradesh, Nagaland, Manipur and Mizoram. The ICAR-NRC on Mithun, Medziphema has taken an initiative to study different diseases of mithun from the NEH region. We have documented occurrence of different parasites their epidemiology, pathology and molecular identity with a major emphasis on control of different parasites including helminth, protozoa and ticks infesting mithun.

We hope that this detail compilation about various parasites will definitely helpful to take up advance research work and developing a diagnostic kit in future. Besides, a proper control measures will improve the income generation by increasing the growth rate which ultimately and boost the mithun husbandry in the region.

Jayanta Kumar Chamuah
Scientist, Veterinary Parasitology

DIRECTOR'S MESSAGE

Mithun (*Bos frontalis*), a rare bovine species, found in the northeastern part of India along the Indo-Myanmar border and few adjoining countries like Myanmar, China, Bhutan, and Bangladesh. In India, it is found in Arunachal Pradesh, Manipur, Mizoram, and Nagaland which constitute about 90% of the World's mithun population. Mithun is considered a ceremonial animal in the tribal culture of the major tribes of mithun rearing states. However, mithun is primarily reared as a source of livelihood for the resource-poor farmers of the region. Mithun not only provides financial security during emergencies like medical expenses, education, and marriage, etc. but also acts as an important component of the barter system.

Though, mithun is considered as a hardy animal and appeared to be resistant/ less susceptible to many infectious diseases. However, no systematic studies have been carried out to substantiate the claim. Mithun can survive in varying climatic conditions ranging from 300 to 3000m (MSL). Mithun, like other bovines, is susceptible to many parasitic diseases which may lead to reduced productivity and greater economic loss to the mithun farmers.

The climatic conditions prevailing in the north-eastern hilly region of the country like relative humidity of 70-80%, atmospheric temperature of 15-35°C, and varying soil pH of 6.5-8.5 are considered to be conducive for optimum development of different parasite larvae and thus making it an ideal atmosphere for the propagation of different parasite species. Various studies have been conducted on epidemiology, genetic characterization, and diagnostic aspects of the parasites affecting mithun in our country and among these, infection with helminth parasites are one of the important factors contributing to decreased productivity in mithun, both in terms of meat and milk.

An attempt has been made by the authors to document different parasites that occurred in mithun, their clinical symptoms, line of treatment, and control measures. The bulletin has been written in a very concise format and easy to understand keeping in view to educate the mithun farmers, veterinary professionals students, and other stakeholders.

I hope this compilation will serve its purpose and will prove beneficial for all the stakeholders.

M H Khan
Director (Acting)

CONTENTS

Amphistome infection in mithun and their control measures

Introduction

- Intestinal amphistomosis is very common in mithun of Arunachal Pradesh.
- Immature amphistomosis was also recorded from Khonoma village of Nagaland.
- An outbreak of amphistomosis is being confined to post-monsoon and drier months of the year.
- In enzootic areas, the early infection may be acquired by grazing on marshy areas on inundated pasture during the preceding rainy season.
- Mithun may pick up infection from the snail infested contaminated pasture and forest.
- Late outbreaks are due to grazing on green vegetation surrounding tanks, ponds, pools, and banks of rivers infested with snail.
- Previous infection and the age of the host provide some protection against reinfection and hence the acute disease is usually seen in young animals while older animals are capable of withstanding massive exposure and seed the pasture with eggs.

Fig: 1. Adult *Calicophoron calicophorum*

Fig: 2. Affected rumen with *C. calicophorum*

Pathology:

- In paramphistomosis, pathological changes are due to mechanical damage caused by immature fluke to the mucosa of the affected part of gastrointestinal tract after excystment in the small intestine. The immature paramphistomes penetrate the mucosa and become attached by drawing a plug of mucosa in their acetabulum.
- Being strangulated, the piece of the affected part of mucosa involved become necrosed and eventually sloughed off. This produces erosive lesions and mucosal petechiae cause intestinal discomfort which eventually leads to inapetance or anorexia in the host.
- The anorexia coupled with impaired food assimilation results in loss of weight. The small intestine becomes hyperaemic and oedematous leading to partial occlusion of the bile duct which ultimately results in necrosis of the bile duct and epithelium.
- The animal loses plasma albumin by seepage through the erosion in digestive tract. It also develops polydypsia which along with anorexia and decomposition of plasma protein in the intestine account for loose and foetid nature of faeces.
- Reduced plasma protein concentration results in hydropericardium, hydrothorax, pulmonary edema, ascitis, and also bottle jaw. Pulmonary edema, starvation, and exhaustion appear to be the immediate cause of death.

Clinical symptoms:

- The most common symptoms of acute paramphistomosis are edema, anorexia and diarrhoea (Prodormal syndrome).
- It starts as a small flabby swelling in the subcutis in the inter mandibular space which gradually increases and extends up to cheeks, dewlap and sternum in mithun.
- This leads to development of edema and anorexia. But the animal generally shows increase thirst, it takes a small quantity of water frequently i.e. polydypsia and may keep its muzzle deep in water for a considerable period.
- Within a week appearance of edema, the animal develops diarrhoea. The faeces become looser day by day till this becomes watery and foetid.
- In chronic cases, rectal haemorrhage may occur due to persistent straining which results in presence of blood clots in the faeces.

- In severe cases, especially in mithun and allied bovine species, the diarrhoea is projectile as in the rinderpest but the disease can be differentiated from the later by the absence of mouth lesion.
- Afterward sphincter control frequently lost and faeces are passed involuntarily with the advancement of diarrhea and the animal generally shows the symptoms of anaemia.
- The visible mucous membrane becomes pale and paler, almost white and odourless.

Treatment:

Treatment of the affected animals:

1. Rafoxanide @ 1g/100kg body weight orally
2. Triclabendazole @ 900mg/100kg body weight orally
3. Albendazole @ 7.5-15mg/kg body weight orally

Vector Control:

Removal of snail vector from the chain of life cycle of paramphistome is theoretically most effective method of disease. It should constitute an essential part of control. Various methods controlling snails are –

1. Removal of vegetation
2. Drainage of swamps and other places which are the breeding grounds of snail
3. Manual picking of snails
4. Application of chemicals such as niclosamide, intrityl morpholine, sodium pentachlorthionate, ammonium sulphate, copper sulphate etc. which have high molluscidal efficiency. The choice of method depends upon the prevailing local condition and availability of resource.

Biological control:

1. Predation of snail
2. Competition with other snails.
3. Introduction of parasite of snail intermediate host

4. Introduction of organism which consume the food of other snail.
5. Use of organism which attacks larval stages
6. Use of parasitic larval trematode that destroys the intermediate stage of pathogenic fluke in the snails

Agent:

Vertebrate predator: Ducks and fishes.

Managemental control :

- Control of grazing around water resources is therefore the utmost importance for the prevention of disease.
- All infested paddock, marshy low lying areas and areas surrounding water resources should be closed for grazing by means of fencing. Herbage from such areas must be converted to hay and silage before use.
- Clean drinking water should be available all the time. If water from doubtful sources has to be used, then shallow creeks can be constructed and must be treated with molluscide.
- In paddy growing areas, use of raw manure as biofertilizer in the field results in high infection of snail. This practice should not be adopted and farmer should be educated on the use of compost manure instead of raw manure.
- Treatment should be continued before pre-moonsoon and post-moonsoon season.

Fasciolosis in mithun and their effective control measures

- Fasciolosis has been found to cause major clinical manifestation leading to mortality of mithun.
- Fasciolosis is caused by the parasites *Fasciola gigantica* (tropical liver fluke) and is a relentless constraint on the growth and productivity of mithun.
- It has been considered as an economically important parasitic disease due to the substantial decrease in production and heavy monetary losses to livestock industries.

Fig: 1. Adult *Fasciola gigantica*

Fig: 2. Adult parasites of *Fasciola*

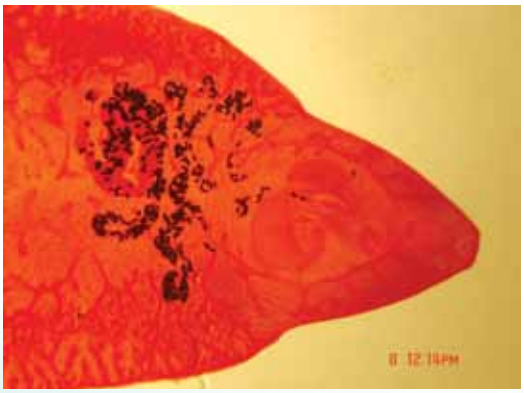

Fig: 3. Anterior portion of *F. gigantica*

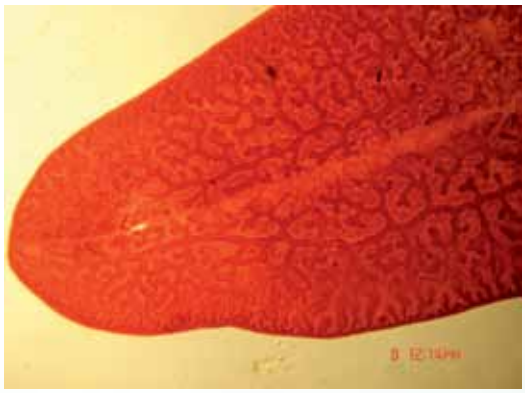

Fig: 4. Posterior portion of *F. gigantica*

Epidemiology:

- The occurrence of fasciolosis is influenced by a multifactorial system, which comprises hosts, parasite and environmental effects.
- The life cycle of *Fasciola* is indirect with snails of the genus *Lymnaea* acts as the intermediate host.
- In the natural foci of fasciolosis, the parasite and their intermediate as well as final hosts form an association, posing a potential epidemiological threat.
- In mithun, the occurrence of liver fluke infection is very less. *Fasciola gigantica* has been recognized as the causative agent for fasciolosis in mithun (Chamuah, 2005; Chamuah *et. al.* 2020).
- The geographical distribution of *Fasciola* spp. depends not only on the presence of suitable aquatic *Lymnaeid* snail but also on favourable climatic and ecological conditions.
- In most of the tropical developing countries, the temperature is generally favourable for the development of both the fluke and their intermediate host, but due to the variations in the precipitation and humidity, there are fluctuations in the development of snail and free-living stages of parasites.
- There is a marked increase in the reproduction of snails in the rainy season that leads to a peak in snail population towards the end of the season. This trend slows down or completely ceases during the dry or cold periods resulting in less snail population in the dry season.
- This is accompanied by a considerable fluctuation of herbage infestation and survivability of metacercariae.
- The ultimate determinant of the epidemiology of the parasitic disease is the rate of egg production by the adult flukes which subsequently influences the degree of pasture contamination.
- In addition, the grazing habits and management of the animals may significantly influence the epidemiology of liver fluke infection.

Pathology:

- In acute fasciolosis, traumatic hepatitis condition is produced by the simultaneous migration of large number of immature flukes and is seen mainly towards the end of summer when large number of cercariae are shed onto herbage.

- There is extensive destruction of liver parenchyma and marked haemorrhage. Rupture of liver capsule may occur with haemorrhage into the peritoneal cavity.
- Mithun may die within a few days of the onset of clinical sign. The liver is enlarged, pale, friable and shows numerous haemorrhagic tracts on the surface.
- In less acute forms of disease, the liver is covered with migratory tracts but an infiltration of white cell is more evident and early fibrosis may be seen.
- This sub acute type may be superimposed on an existing chronic infection and then a more marked cellular response may be seen. The clinical entity of the acute and sub acute forms are seen in animal of all ages and stages of nutrition.
- In chronic fasciolosis, in mithun and other bovine species, calcification of bile duct occur which reassemble stem of clay pipe, giving the common name of "**PIPE STEM LIVER**" to the infection.
- A hyperplastic cholangitis is caused by the presence of adult flukes in the bile ducts. The hyperplastic biliary mucosa becomes permeable to plasma proteins, particularly albumin and this together with blood sucking activities of the adult flukes accounts for hypoalbuminaemia and hypoproteinaemia evident during the infection.
- In mithun, calcification of bile duct most commonly observed in north eastern hilly region of India.

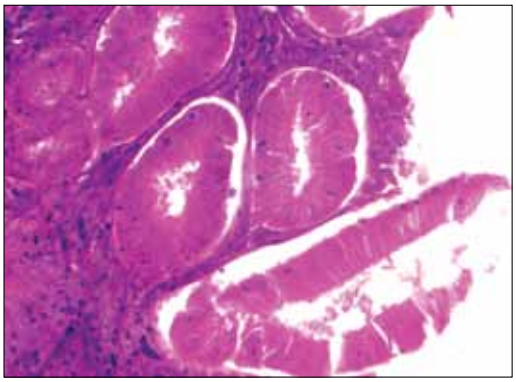

Multiple adult *Fasciola* parasites seen embedded in the liver parenchyma. 20X. H&E (Chamuah *et al*. 2020b)

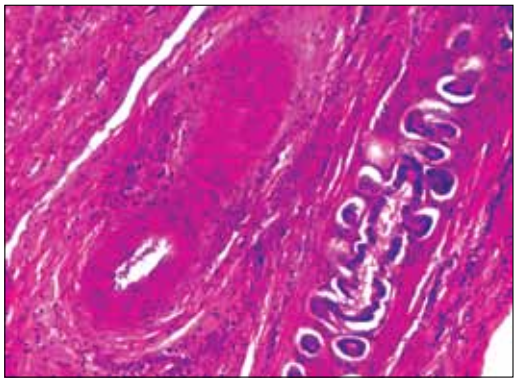

Parasitic tract of the parasite with fibrous proliferation is observed in the liver parenchyma. 20X. H&E (Chamuah *et al*. 2020b)

Clinical symptoms:

- In acute cases, the animal dies suddenly, blood stained froth appears at the nostril and blood discharges from anus as in case of anthrax.
- In chronic cases, the first signs are seen at a time when the young worms burrowing the liver parenchyma. Mithun shows increasing anaemia followed by lack of vigour
- The appetite diminishes, mucous membrane becomes pale and oedema develops in the intramandibular region (Bottle jaw). The skin becomes dry and rough. There is debility, emaciation, general depression followed by diarrhoea, constipation and slight fever.
- In mithun most characteristics signs are digestive disturbances; constipation is marked and followed by fluid foetid diarrhoea. Bottle jaw condition is the most predominant clinical findings of chronic fascioliasis.

Chemical Pathology:

- A profound anaemia and changes in the serum proteins are found.
- As the infection progresses and adult parasites migrate to the bile ducts, there will be marked hypoalbuminemia, hypoproteinemia and hypoglobinemia.
- These changes are associated with the progressive and marked loss of plasma proteins, particularly albumin into the gastrointestinal tract through the blood sucking activities of the adult flukes and through leakage of protein through the bile duct epithelium.

Control :

1. Treatment with different anthelmintics before premoonsoon and post monsoon
    - Nitroxynil @ 10mg/kg b.w. s/c
    - Rafoxanide @ 7.5mg / Kg b.w. orally
    - Closantel @ 10mg/ kg b.w. orally
    - Oxyclozanide @ 1g/100kg b.w. orally
    - Albendazole @ 7.5mg/kg b.w. orally
    - Triclabendazole @ 7.5mg / Kg. b.w. orally
    - Clorsulon @ 2.0 mg / Kg b.w. orally
    - Diamphenethiade – 100 mg / kg. (More activity against the immature fluke).

2. Proper feeding and management of animals.
3. Controlling of snail intermediate host with different molluscidal drugs.
4. Control of low lying grazing areas by means fencing with barbed wires
5. Control of wild animals which act as reservoir hosts

Pimply gut in mithun and their management

- Pimply gut is commonly observed in mithun due to repeated and chronic *Oesophagostomum* larvae infection and as a sequele to immunopathological reaction.
- Animals died due to chronic digestive disturbances and malabsorption of food nutrients.

Fig: 1. Greyish white nodule observed in the rectum

Fig: 2. Enteritis in the rectum

Pathology:

- In our farm condition, pimply gut is commonly observed in dead mithun calves and is due to repeated infection and chronic exposure of *Oesophagostomum* infection.
- In this condition, extensive nodules is observed in entire rectum and large intestine.
- The nodules were greyish white in colour ranging in size from pinhead to a pea and entire intestinal wall was thickened, congested and oedematous with mild haemorrhages (Chamuah *et al*. 2016c).
- The rectum revealed congestion and haemorrhage of mucosal and submucousal layers.

- Most of the cases, encysted larvae were visible in the muscularis mucosae and in the sub mucosa surrounded by eosinophilic infiltration and fibrous connective tissue proliferation.
- Chronic enteritis is a common sequale of this condition and it is commonly evidenced by mononuclear cell infiltration comprising mostly of machrophages, lymphocytes and eosinophils.

Different photograph of mithun calves showing affected pimply gut condition (Chamuah *et al.* 2016c)

Fig: 3. Mithun calf showing chronic wasting and rough hair coat

Fig: 4. A dead Mithun calf showed profuse diarrhea

Fig: 5. Nodule formation in large intestine

Fig: 6. Extensive nodule formation in the rectum

Fig: 7. Congestion and thickened mucous layer of the large intestine.

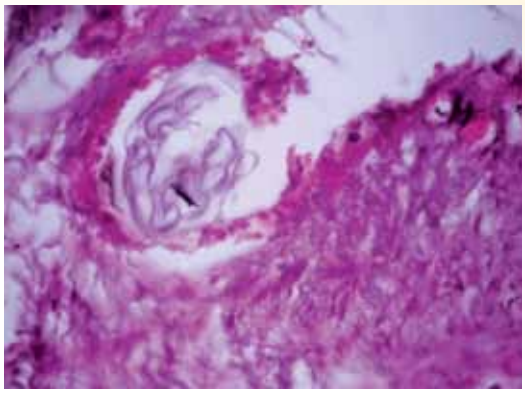

Fig: 8. Microscopic photo of rectum showing encysted larvae, eosinophilic infiltration and fibrous tissue proliferation

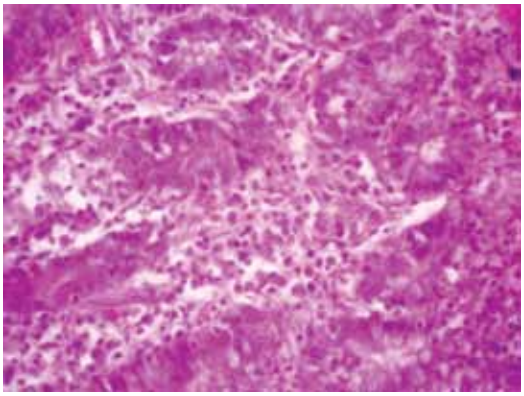

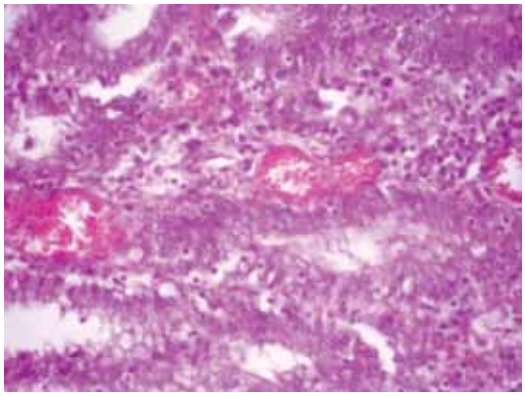

Fig: 9. & 10. Congested blood vessel and haemorrhage

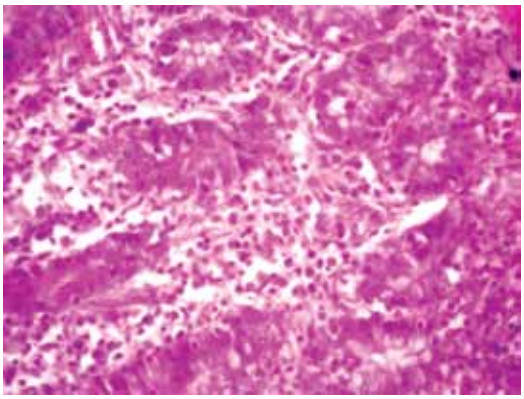

Fig: 11. Chronic enteritis with mononuclear cell infiltration (macrophage, lymphocyte and eosinophils)

Clinical symptoms:

- The resulting nodules were often associated with diarrhoea of the infected mithun calves and inability to digest food accompanied by extreme weight loss, weakness resulting in death.
- Mithun calves showed hunched back condition and have a stiff gait whereas in less severe infection intermittent diarrhoea with weight loss and reduction in meat production.
- In farm condition, management of the mithun calves along with browsing habit of grazing significantly influence the epidemiology of *Oesophagostomum* and other *strongyle* infection in mithun.

Treatment and prevention:

- Treatment of infected animals with broad spectrum anthelmintic like Albendazole @ 7-15 mg/kg body weight, Fenbendazole @ 10mg/kg body weight and Ivermectin @ 200mg/kg s/c
- Proper hygienic measures should be adopted in farm condition.
- Animals should be dewormed twice in a year i.e. premoonsoon and postmoonsoon.

Parasitic gastrointestinal nematodiasis with special reference to Strongyle infection in mithun

The climatic conditions prevailing along the entire mithun tract extending from the North Eastern Hilly States of India (Arunachal Pradesh, Nagaland, Manipur, and Mizoram), Bhutan, Xingua province of China, Myanmar and Bangladesh are almost similar. The relative humidity of 80% with moderate temperature (15-37°C), high rainfall, and acidic to neutral pH is highly conducive for the growth and propagation of various parasites. The epidemiology of helminthic diseases is determined by a complex interaction of the environment and host-parasite interactions.

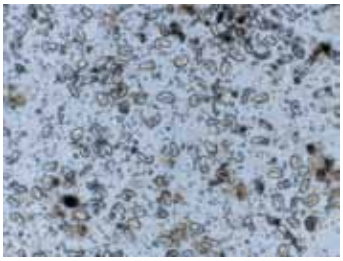

Fig: 1. Eggs of *Strongyloides papillosus*



Fig: 2. Eggs of *Oesophagostomum* species

Fig: 3. Eggs of *Trichostrongylus* species

Fig: 4. Eggs of *Moniezia* species

Fig: 5. Eggs of *Strongyle* species

Fig : 6. Parasite affected animals

(Chamuah, 2014b)

Gastrointestinal nematodes:

- Parasitic gastroenteritis is the major cause of parasitism in mithuns and is one of the major causes of morbidity and mortality among mithun calves (Chamuah *et al.* 2009; Chamuah *et al.* 2013b).
- Among various parasites reported from the mithun are *Haemonchus contortus, Oesophagostomum sp., Trichostrongylus sp., Mecistocirrus sp., Cooperia sp.,* and *Trichuris sp*. (Chamuah, 2014b).
- The *Toxocara vitulorum, Strongyloides papillosus* and *Bunostmum phlebotomum* and *Haemonchus contortus* are the major cause of anemia and mortality in mithun calves.

Epidemiology:

- The development, survival, and transmission of eggs and infective larvae are influenced by climatic and environmental factors such as temperature, humidity, precipitation, and population density.
- Change in the combination of these factors causes seasonal fluctuation in the availability of infective larvae and subsequently in the prevalence of infections and worm burdens in the animals.
- In general, active development occurred during most of the rainy season and grazing animals harbor a variable but significant number of worms.
- In areas with a distinct rainy and dry season, the majority of third-stage larvae (L3) acquired, undergoes arrested development at the end of the rainy season, and faecal egg counts decline and remain consistently low during the dry season.
- At the onset of the rainy season when pasture larval challenge and intake of infective larvae are high there is a sharp increase in the egg output.
- While the pattern described is the most common, there may be limited plots surrounding drinking places and permanent ponds which may be sufficiently humid to maintain optimum larval development and transmission round the year.
- The phenomenon of periparturient rise in faecal egg count is of great importance in the epidemiology of gastrointestinal nematodes of ruminants and has been extensively reported in mithun.

Clinical symptoms:

- Reduce body weight
- Diarrhea followed by constipation
- Pale mucous membrane
- Anemia

Treatment:

1. Treatment of the affected animals with right choice of anthelmintic before premoonsoon and postmoonsoon as a preventive measure.
2. Ivermectin @ 200mg/kg body weight subcutaneously
3. Albendazole @ 7.5-15mg/kg body weight orally
4. Fenbedazole @ 10-20 mg/kg body weight orally
5. Proper housing, feeding and management of animals.
6. Reduce pasture contamination with proper measure.

Prevention and Control:

1. Proper deworming and treatment of affected animals with broad-spectrum anthelmintic.
2. Maintaining hygiene of animal houses with proper disposal of affected dung and urine.
3. Ploughing of farm premises and planting with feed and fodder which have anthelmintic properties.
4. Medication of animals with anthelmintic before and after monsoon regularly.

Prevention and Control of *Mecistocirrus digitatus* infection in Mithun Calves

- Mithun like other domestic animals is also prone to suffer from different disease conditions due to congenial climate and atmosphere for survival of parasites.
- However, incidence and intensity of different helminth parasites is very less in hilly areas due to peculiar topography and high rainfall.
- Among different parasitic diseases, *Mecistocirrus digitatus* is one of the causative agents for mithun calves mortality.

Epidemiology:

- The occurrence of *Mecistocirrus* in an area is influenced by a multifactorial system, which comprises hosts, parasite and environmental effect.
- However, high humidity, at least in microclimate of the faeces and the herbage is also essential for larval development and their survival.
- The development, survival and transmission of eggs and infective larvae are influenced by climatic and environmental factors like temperature, humidity and precipitation.

Fig: 1. Adult *Mecistocirrus digitatus* (Chamuah *et al*. 2017b)

Fig: 2. Adult parasites in the abomasum (Chamuah *et al*. 2017b)

- The optimum temperature for the development of maximum number of larvae is in the range of 18 °Ċ-26 °Ċ and humidity as high as 100 % although some development can occur down to 80 %.
- However, even in dry weather where the ambient humidity is low, the microclimate in faeces or at the soil surface may be sufficiently humid to permit continual larval development.
- These factors often lead to seasonal fluctuations in the availability of infective larvae which subsequently affects the prevalence of infections and worm burdens in the host.
- These epidemiological factors could be the same for mithun under farm condition, when compared to mithun under free range condition where, these factors are not severe for precipitation of disease in the latter.
- The phenomenon of periparturient rise in faecal egg count of female animals also plays a major role in the epidemiology of gastrointestinal nematodes in mithun. This could be due to release of prolactin hormone which causes temporary relaxation of immunity in pregnant animals.

Clinical sign and symptoms

- The clinical signs are of complete palor of the mucous membrane, dehydrating body, severe anaemia and dark bloody faeces.
- The symptom of iron-deficiency anaemia, intermittent constipation, loss of appetite, weight loss and progressive wasting is also observed.

Pathology

- In histopathological study, lung with emphysematous, showed pronounced interstitial pneumonia followed by severe thickening of alveolar septa and bronchial wall, haemorrhages with connective tissue proliferation and infiltration of leucocytes around the bronchial wall (Chamuah *et al.* 2020a).
- Liver showed mild haemorrhages of hepatocytes and congestion in sinusoidal space. In abomasum, adult parasites were embedded in mucosa and sectioning of adult parasites were seen with full of eggs.

- In large intestine, there was necrosis and degeneration of colonic villi and loss of normal architecture. There was also evidence of hyperactivity of acinar cells, fibrous tissue proliferation with polymorphonuclear cell infiltration.
- An apical tip shows degenerative changes, adhesion with mild fibrous tissue proliferation. In small intestine, there was congestion, oedema with thickening of sub mucosa as well as erosion of intestinal villi in certain areas, adhesion and fibrous tissue proliferation.
- In spleen, there was depletion of spleenic venule, congestion of spleenic pulp and haemorrhages surrounding the spleenic venule.

Treatment

1. Treatment of animals with Ivermectin @1ml/50 kg body weight subcutaneously.
2. Albendazole @ 15mg/kg body weight orally.
3. Fenbendazole and Paraziquantel combination @ 10-20mg/kg body weight orally are highly effective.

Control:

1. Regular deworming of animals before and after monsoon.
2. Proper housing and management of farm animals.
3. Zero grazing and practice of stall feeding in farm management systems.
4. Proper care and nutrition to farm animals.
5. Proper and balanced feeding of new born calves.

Toxocara vitulorum infection in mithun and their treatment

- *Toxocara vitulorum*, is commonly found in the small intestine of mithun calves and is a common cause of mithun calves mortality leading to huge loss of livestock industry.
- Poor management along with less immunity or poor nutrition are more prone to infection and often result in fatalities of calves.
- It is translucent in appearance.

Epidemiology:

- The mode of transmission is through prenatal and lactogenic route (from mother to offspring).
- Ingestion of larvated eggs by the adults do not directly leads to patent infection. Larvae were migrated through tracheal and somatic route to different internal organs and remains dormant there until parturition of female animals and prenatal infection established during this time.
- Upon ingestion of larvated egg from the environment by adults, there will be subsequent hatching of the larvae and penetration to the small intestine and remaining as a hypobiotic larvae in the internal organs.
- During parturition time, there will be temporary relaxation of immunity. Subsequently, the larvae become activated around parturition and migrate to udder tissue.

Fig: 1. Adult *Toxocara vitulorum* (Chamuah *et al.* 2017b)

Fig: 2. Catarrhal enteritis in the small intestine

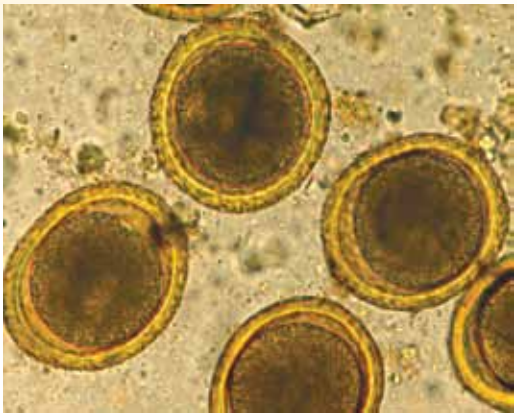

Fig: 3. Eggs of *T. vitulorum*

Fig: 4. Obstruction of small intestine by adult parasites

- Young one acquires the infection through the lactogenic route and adult worm established in the small intestine.
- Predominant clinical signs in calves are diarrhoea and steatorrhoea.

Pathology:

- Catarrhal enteritis
- Impaction and obstruction of intestine
- Perforation of intestine

Clinical symptoms:

- Progressive loss of body coat
- Emaciation, faces may contain blood and mucous
- Mud coloured diarrhoea
- Pot bellied condition

Treatment:

- Piperazine is the drug of choice against *Toxocara* infection
- Ivermectin @ 200mg/kg subcutaneously
- Treatment of pregnant mother with Levamisole @ 7.-15mg/kg body weight subcutaneously.

Setaria digitata in mithun and their control measures

- *Setaria digitata* is a long milky white worm with tapering and spirally coiled hind ends most commonly found in the peritoneal cavity of mithun in Arunachal Pradesh and Nagaland.
- The larvae of this filarial nematode are known as microfilaria which is found in the blood of the host. Its life cycle is indirect and culicine mosquito acts as intermediate host of the parasite.
- Larval forms are considered to be pathogenic.
- Even though the adult worms are generally considered to be non- pathogenic, they may be responsible for mild fibrinous peritonitis.

Epidemiology of *S. digitata* infection:

- Epidemiology of *S. digitata* infection is influenced by climate and availability of vectors. This nematode is transmitted via mosquito vectors belonging to the genera *Aedes, Culex, Anopheles* and *Armigeres* (Tung *et al*., 2004).
- Within 8-10 days following ingestion by mosquitoes, these microfilariae moult twice to develop into an infective third stage larvae (L_3 larvae) in the thoracic muscles of the vector.
- Infected mosquitoes are then capable of transmitting L_3 larvae to other susceptible hosts during their blood meals. In the host, the L_3 larvae will reach sexual maturity within 8-10 months, thus completing the life cycle.
- Briefly, the intensity of infection with microfilaria of *S. digitata* was higher in older animals than in younger animals and prevalence was higher in warmer seasons due to the pronounced activity of mosquitoes.
- Also, the gender of the host does not show any influence on the occurrence of *S. digitata* infection in mithun.
- The congenial environment of the north eastern region of India favours the survival and propagation of mosquito vectors. So, in order to reduce the incidence of *S. digitata* infection in mithun, vector control should be attempted with proper insecticide.

- Therefore, utmost care and advice should be given to the mithun owner for reducing parasitic burden in order to increase the production performance of this pride animal of the north eastern hilly region of India.

Fig: 1. Adult *Setaria digitata*

Fig: 2. Microscopic view of anterior portion of *S. digitata*

Pathology:

- In addition to the peritoneal cavity, the adult worms of *S. digitata* was also reported to be present in the urinary bladder, eye, epicardium of the heart and in the lungs and mesenteric lymph nodes.
- In *S. digitata* infection, cerebrospinal nematodiasis (epizootic cerebrospinal setariosis or kumri or lumbar paralysis) is one of the severe conditions caused by microfilariae of *Setaria* species. The condition is caused by the erratic migration of microfilariae into the central nervous system of unnatural hosts such as horses, sheep and goats. Congenital case of setariosis has also been reported.

Control measures:

1. Treatment of the affected animals with right choice of the anthelmintic.
2. Controlling of mosquitoes by means of chemical, managemental and biological measures.

Thelazia infection in mithun

- The surface cuticle of *Thelazia* spp. is made of transverse striations which give the worms a characteristic serrated appearance.
- Moreover, the occurrence of *Thelazia* species infection in the form of corneal opacity in the mithun is very common in Arunachal Pradesh and Nagaland.
- The report about *Thelazia* infection in mithun demands special attention for both mithun rearers and farmers to take special care against this parasite.
- Grossly, the specimens are thin, milky white in colour and 1.2-1.5 cm in length. Microscopically the worms are having prominent cuticular transverse striations mouth cavity is short and broad, widest at the middle.
- This rough cuticle of the worm is responsible for irritation and inflammation of the cornea of the host.
- However, molecular identification of parasites based on marker genes are under process.

Epidemiology:

- The spirurorid genus *Thelazia* Bosc, 1819 are nematodes that infect the conjunctival sacs and lacrimal ducts of domestic animals including mithun and wild ruminants which are transmitted by flies of the genus *Musca*.
- Adult female worms lay live first-stage larvae (L1 larvae) in the ocular secretions.
- These larvae will be ingested by the flies and will develop to the infective third-stage larvae. These larvae are re-infected onto mithun eyes during feeding by the infected flies.
- The life cycle occurs over 2-3 months, and *Thelazia* spp. larvae may overwinter in *Musca* flies.
- Infection may be found year round with more number of incidences during warm seasons when the activities of flies are pronounced.
- However, report about the occurrence of *Thelazia* sp. infection in mithun is very scanty and has been most prevalent in Itanagar areas of Papumpare district of Arunachal Pradesh.

- There was also record of the presence the *Thelazia* sp. from the conjunctival sac and lacrimal duct of mithun in Arunachal Pradesh.

Clinical symptoms:

- Conjunctivitis,
- Keratitis
- Corneal opacity
- Corneal ulceration
- Excessive lacrimation
- Photophobia.

Fig: 1. Corneal opacity due to *Thelazia* infection

Fig: 2. Adult *Thelazia* species in the eye

Fig: 3. Microscopic view of *Thelazia* species

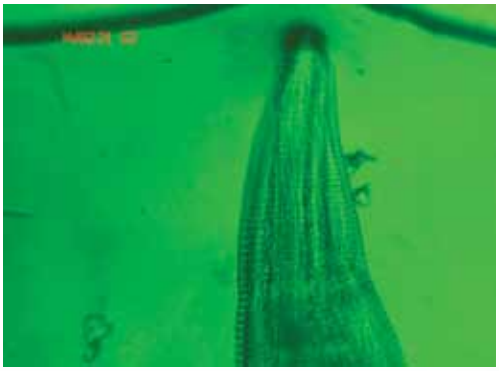

Fig: 4. Microscopic view of tail portion of *Thelazia* species

Prevention and control of *Thelazia* infections:

- The key element to avoid eye worm infections on mithun is to ensure adequate protection against houseflies and other nuisance flies, especially during the fly season.
- Control of houseflies and nuisance flies strongly depends on manure and waste removal in farms, and general hygiene measures in gardens, recreational areas, etc., especially eliminating humid habitats and any accumulation of organic refuse where the flies may breed.
- Among the anthelmintics available for worm control, several macrocyclic lactones have shown systemic efficacy against established *Thelazia* infections, but not always at the usual recommended treatment regimes, which has to be determined by a veterinary doctor.
- Among macrocyclic lactone groups, ivermectin, abamectin and doramectin are effective for *Thelazia* infection in mithun.
- Efficacy has also been reported for fenbendazole and levamisole.

Moneiziasis in mithun and their management

- The cestode infection is one of the most common problems faced by mithun from this north eastern part of the region.
- The species of *Moniezia expansa* and *M. benedeni* not only impairs the digestive function but also reduce the productivity of the animals.

Epidemiology:

- The occurrence of tapeworms is greatly influenced by the epidemiology of parasites and environmental factors.
- The presence of suitable intermediate host for cestode and favorable climatic condition, both determines the epidemiology and prevalence of parasites in animals.
- The cysticercoids, infective stage of tapeworms in oribatid mite, initiates the infection after ingestion of contaminated grass by the animals.

Pathology

1. Obstruction of small intestine and sometimes perforation of intestine
2. Catarrhal enteritis

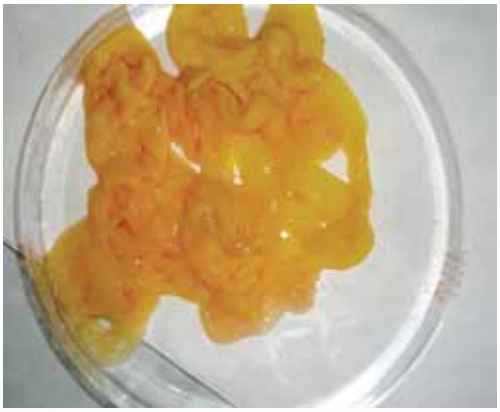

Fig: 1. Segments of *Moniezia benedeni*



Fig: 2. Microscopic view of *M. benedeni*

Clinical symptoms

1. Animal showed potbellied condition along with ruffle hair
2. Reduce growth and production
3. Stunted growth
4. Reduce appetite
5. Reluctant to movement and staring look

Treatment and prevention:

1. Treatment with combination of fenbendazole and paraziquantel orally is very effective.
2. Ivermectin @ 200ug/kg body weight subcutaneously.
3. Ploughing of farm premises for the control of oribatid mite.

Hydatid Cyst in Mithun

- Hydatidosis caused by metacestode of *E. granulosus* is a serious concern and endemic in many parts of India, due to high morbidity and considerable economic loss.
- In India, several factors contribute to the transmission of infection including, cultural, socio-economical, agricultural, and environmental factors.
- In addition to this, lack of education and knowledge about the life cycle of the *E. granulosus*, as well as the lack of legislation for meat inspection and offal disposal at local abattoirs, contributes to an immense increase in transmission among livestock.

Etiology

- Amongst these, cystic echinococcosis caused by the larval stage (hydatid cyst) of the smallest canine cestode, *Echinococcus granulosus* is the most economically important disease in livestock.

Economic loss

- Economic losses arise not only from the condemnation of infected viscera, but also from a reduction in yield and quality of meat, milk, wool, hide value, birth rate, and fecundity.
- CE is considered an emerging and re-emerging zoonotic disease in many parts of the world.
- Recently, the World Health Organization (WHO) has included echinococcosis as part of a Neglected Zoonosis subgroup in its 2008–2015 strategic plans for the control of neglected tropical diseases.

Epidemiology and Life cycle

- Two hosts are involved in the life cycle of *E. granulosus,* the definitive host being carnivores and the intermediate hosts include ungulates both domestic and wild animals and humans.
- The adult tapeworm lives in the small intestine of carnivores and intermediate larval stages (hydatid cyst) develops in the internal organs of mithun including

human which acquire the infection through accidental ingestion of the tapeworm eggs.

- Transmission and maintenance of echinococcosis are dependent on complex interactions of several factors including environmental, host, and pathogen. Several such factors are of local epidemiological significance and identification of such factors is important in the effective implementation of control measures.

Clinical symptoms and pathology:

- Clinical symptoms will be varying according to the location of cyst.
- Sometimes ruptured cyst will cause anaphylaxis in patients and pressure atrophy of the affected organ.

Fig: 1. Hydatid cyst in liver

Fig: 2. Hydatid cyst in lungs

Fig: 3. & 4. Hydatid cyst in spleen

Diagnosis:

1. Post mortem: Surveillance for cystic echinococcosis in animals is difficult because the infection is asymptomatic in mithun. Confirmative diagnosis and detection of *hydatid* infection in animals is done during post mortem only.
2. Serological: Serological tests based on crude parasitic extract/ hydatid cyst fluid results in cross-reaction with other taenid species rendering it less sensitive.
3. The diagnosis of extrahepatic echinococcal disease is more accurate today because of the availability of new imaging techniques, like X-Ray and Ultrasonography etc.
4. Advanced molecular techniques are also employed for ante-mortem diagnosis.

Treatment

- Chemotherapy like Albendazole @ 10-15mg/kg body weight orally
- Mebendazole @ 5-10mg /kg body weight orally
- Ivermectin@ 1ml/50kg body weight subcutaneously

Prevention and control measure:

- Adopting of strict hygienic measures by people.
- Regular screening and meat inspection in butcher house against meat borne diseases
- Regular deworming of the definitive host (dogs) with the right choice of anthelmintic.
- Mithun should be dewormed twice a year i.e pre-monsoon and post-monsoon.
- Preventing access of dogs to mithun carcasses or slaughter wastes of animals, households, abattoirs etc.

Coccidiosis in mithun calves and their management

- Among enteric tissue protozoa infection, coccidiosis is regarded as one of the commonly reported species with high morbidity and less mortality in managemental condition.

Causative agents:

The common *Eimeria* species reported in mithun are *Eimeria bovis, E. zuernii, E. ovoidalis, E. bukidonensis E. auburnensis, E. ellipsoidalis, E. subspherica* and *E. albamensis*.





Fig: 1. & 2. Oocyst of coccidian species

Epidemiology

- The prevalence of Eimerian species is generally highest in pre-monsoon than that of other season.
- Infection with Eimeria species has been reported to be in all age groups of mithun.
- Comparatively, the pathogenicity has been observed to be always higher in young mithun.
- The severity of eimeriasis in ruminants may be correlated with different managemental factors. The incidence is higher in animal herds reared under semi-intensive system with unhygienic condition.

- On the contrary, the incidence of eimeriasis is compared to be low in animals raised under free-range system.

Clinical sign and symptoms

1. Anorexia
2. Weakness
3. There is sudden onset of profuse foetid diarrhoea containing mucus and flecks of fresh blood with straining of the perineum and tail.
4. Straining with partial eversion of the rectum may occur in severe cases. Affected animals do not have an elevated rectal temperature but their appetite is greatly reduced and they develop a gaunt appearance.
5. More usually, chronic wasting and poor appetite are the presenting signs.
6. Morbidity is high but mortality, even in severe cases, is low.

Treatment:

Drugs that can be used for therapy of clinically affected animals include sulfaquinoxaline (6 mg/lb/day for 3–5 days) and Amprolium (10 mg/kg/day for 5 days).

Control and Prevention

- Proper housing, feeding and management of farm premises
- Regular washing of shed with disinfectant and should be kept as dry as possible.
- Feeding and watering equipment should be cleaned and protected from fecal contamination.
- Avoid overcrowding and dry bedding should be provided.
- Infected animals should be isolated as soon as possible to avoid exposure of infected manure to other mithun.

Ticks in mithun

- Ticks cause huge economic losses as a result of injury, tick pyrexia, and tick paralysis, besides transmitting various pathogens including bacteria, virus and protozoan parasites to the host animals.
- The environmental conditions of the region greatly favor the survival and reproduction of ectoparasites leading to poor body condition, reduced growth rate and decrease in production performance of animals.
- In seasonal study, the prevalence of *Rhipicephalus microplus* was recorded to be highest in the summer season (Chamuah *et al*. 2012).
- The rainfall has been indicated as the limiting factor for the distribution of ticks.

Different ectoparasites in mithun:

- **Ticks (Chamuah *et al*. 2016a; Chamuah *et al*. 2016b)**
  1. *Rhipicephalus microplus*
  2. *Amblyomma testudinarum*
  3. *Ixodes ovatus*
  4. *I. acutitarsus*

Fig: 1. *Ambylomma testudinarum*

Fig: 2. *Rhipicephalus microplus*

Fig: 3. Mithun infested with ticks

Fig: 4. Mithun infested with seed ticks

Fig: 5. Collection of ticks from mithun

Pathology caused by ticks:

1. Anaemia
2. Dermatosis
3. Inflammation
4. Swelling
5. Itching
6. Ulceration of the skin

7. Tick paralysis due to neurotoxin present in saliva of tick species.
8. Tick toxicosis
9. Transmitter of different viral, bacterial, protozoal, and rickettsial diseases
10. Damage to the hides

Treatment:

1. Insecticide impregnated ear tags and collars
2. Spraying of Amitraz (12.5%) or Deltamethrin (1.25%)
3. Carbaryl powder 5 % as a dust and 10 % as a liquid spray
4. Ivermectin 1ml/50 kg body weight through subcutaneous route
5. Doramectin 1% can be given through subcutaneous route
6. Doramectin 0.05 kg/body weight orally

Preventive measures:

1. Maintenance of cleanliness where animals are kept
2. Removing of cracks and crevices at the farm where animals are kept
3. Use of tick repellent on the coat of animals
4. Daily grooming/combing/brushing of animals can reduce the infestation.
5. Proper management of animal housing and feeding
6. Regular checking of the animal for ectoparasites
7. Stall feeding is also an efficient way of controlling ectoparasites.
8. Bio fencing of the farms with tick repellent trees.
9. Ploughing of the farm premises also reduce the infestation.

Leech Infestation in mithun and its control Measures

- Leech infestation or hirudiniasis is one of the most common problems faced by the mithun rearers in northeastern states of India and in severe cases, leech infests nasal cavity (internal hirudiniasis) of mithun which results in severe respiratory distress leading to death.
- Most of the blood sucking leeches feed as ectoparasites for short period of time, however those that feed on mucous membranes of nasal cavity have been known to stay in orifice for days and weeks.
- Leeches are widely distributed in northeastern hilly regions and it is reported that aquatic leech can infest mucosal membranes accidentally when mithun drinks water from springs and freshwater sources.

Epidemiology, clinical Signs & pathology:

- Leeches are segmented worms, which can suck blood of host as many as nineteen times of body weight. Leeches as pathogenic parasites cause complications such as pain, itching, inflammation, severe anemia, short-term bleeding, hypersensitivity, and anaphylactic reactions on their host.
- The parasite in the respiratory tract has also been reported in animals. Some reports have mentioned that hirudiniasis may cause severe anemia with hemoglobin lesser than 5g/dl. Now-a-days, hirudiniasis is categorized as emerging and reemerging diseases.
- In north eastern region, most common problem encountered in mithun is leech infestation in the body as well as in the nasal cavity and is regarded as one of the greatest nuisances faced by the mithun of this region.
- The leech attaches to the body surface, nasal cavity as well as reproductive organs of the animals.
- It causes death of animals through asphyxia of respiratory system and also invites secondary bacterial infection in the wounded area initiated by leeches.
- The main complication of leech infestation includes anemia, weight loss, respiratory distress, restlessness, haematemesis, haemoptysis, bleeding, vaginal, oral and rectal bleeding and etc.

Fig: 1. & 2. Mithun hoof and nostrils infested with land leech

Fig: 3. Clinically leech infested infested animals

Fig: 4. Recovered leech from nasal cavity

- Besides, it also plays an important role in transmitting different microorganism to host animals.

Prevention and Control measure:

1. Manual removal of the leech from animals body
2. Treatment of animals with Amitraz 12.5% W/V (RIDD) and Cypermethrin 0.1%
3. Flushing of animal's nose with saturated salt solution
4. Injection of Ivermectin in heavy dose
5. Flushing of animals nose with 0.25% formalin solution
6. Avoid drinking of animals in contaminated ponds and stream
7. Fencing of drinking source having leech population
8. In forest, use of repellent like neem oils and citronella oils in animals body in order to avoid land leech infestation

Future Perspective:

Keeping in view of the potentiality of the of NEH region in maintaining free ranging animals in safe and sustainable manner, the cidal and repellent potential of plants can be exploited to develop a natural formulation suitable to NEH states. Due to difficult terrain and minimum trained manpower available in this part of the country, the subject has not been addressed suitably and there is a huge gap in knowledge which is essential for the development of suitable control measures.

References

1. Chamuah, J.K, Lama, S., Dutta, P.R., Raina, O.K. and Khan, M.H. (2016a). Molecular identification of Ixodid ticks of mithun from Nagaland. Indian J Anim Sci **86** (7): 762–763.

2. Chamuah, J.K. (2005). Studies on some aspects of parasites of mithun (*Bos frontalis*). MVSc thesis submitted to Assam Agricultural University, Khanapara, Guwahati-22.

3. Chamuah, J.K., Bhattacharjee, K., Sarmah, P.C., Raina, O.K., Mukherjee, S. (2016b). Report of *Amblyomma testudinarium* in mithuns (*Bos frontalis*) from eastern Mizoram (India). J Parasit Dis **40** (4):1217-1220.

4. Chamuah, J.K., Das, M., Islam, S., Rajkhowa, S., Rajkhowa, C., Chakraborty, A. (2009). Studies on naturally acquired gastrointestinal helminths of mithun (*Bos frontalis*). Vet. Parasitol **23**: 37- 40.

5. Chamuah, J.K., Dutta, B., Borkotoky, D. (2017a). Pathological studies on helminth parasitic infection in mithun (*Bos frontalis*). J Parasit Dis DOI 10.1007/s12639-017-0913-7.

6. Chamuah, J.K., Dutta, P.R., Prakash, Ved., Raina, O.K., Sakhrie, A., Borkotoky, D., Perumal, P., Neog, R. and Rajkhowa, C. (2013a). Comparative efficacy of some plant extracts on *Rhipicephalus (Boophilus) microplus* infestation in mithun (*Bos frontalis*) in the Northeast. Vet. Parasitol **27**(1):5-7.

7. Chamuah, J.K., Jacob, S.S., Sakhrie, A. and Borkotoky, D. (2014a). Serological Prevalence of *Fasciola gigantica* in Mithun (*Bos frontalis*). Int. J. Livest. Res. **4** (5):15-20.

8. Chamuah, J.K., Mech, A. and Perumal, P. and Dutta, P.R. (2015a). Efficacy of chemical and herbal anthelmintic drug against naturally infested gastrointestinal helminthiasis in mithun calves *(Bos frontalis)*. Indian J Anim Res **49** (2): 269-272.

9. Chamuah, J.K., Pegu, S.R., Raina, O.K., Jacob, S.S., Sakhrie, A., Deka, A. and Rajkhowa, C. (2016c). Pimply gut condition in Mithun (*Bos frontalis*) calves. J Parasit Dis **40** (2):252-254.

10. Chamuah, J.K., Perumal, P., Singh, V., Mech, A. and Borkotoky, D. (2013b). Helminth parasites of mithun (*Bos frontalis*) -An overview. Indian J Anim Sci **83** (3): 235–237.

11. Chamuah, J.K., Raina, O.K., Lalrinkima, H., Jacob, S.S., Sankar, M., Sakhrie, A. (2016d). Molecular characterization of veterinary important trematode and cestode species in the mithun (*Bos frontalis*) from north-east India. J. Helminthol. **90** (5): 577-582.

12. Chamuah, J.K., Raina, O.K., Sakhrie, A., Gama, N. (2017b). Molecular identification of *Mecistocirrus digitatus* and *Toxocara vitulorum* in the mithun (*Bos frontalis*) from north-east India. J Parasit Dis DOI 10.1007/s12639-017-0879-5.

13. Chamuah, J.K., Sakhrie, A., Lama, S., Chandra, S., Chigure, G.M., Bauri, R.K. and Siju, S., Jacob, S.S. (·2015b). Molecular characterization of *Setaria digitata* from Mithun (*Bos frontalis*) Acta Parasitol., 60 (3): 391–394; ISSN 1230-2821

14. Chamuah, J.K., Singh, V., Dutta, P.R., Khate, K., Mech, A. and Rajkhowa, C. (2012). Tick infestation in mithun. Indian Vet J **89** (7): 140.

15. Chamuah, J.K. (2014). Epidemiology and Molecular Characterization of Some Important Helminth Parasites of mithun (*Bos frontalis*) of Nagalagand. PhD thesis submitted to Indian Veterinary Research Institute, Izatnagar-243122

16. Chamuah, J. K., Amenti, Borkotoky, D. (2020a). Pathological Studies of *Mecistocirrus digitatus* Infection in Naturally Infested Mithun and Phere (Cross Bred of Mithun). Indian J. Anim. Res. 54(8): 1018-1023.

17. Chamuah, J. K., Borkotoky, D., Amenti, Khate, K., Lalchamliani, Raina, O. K., Khan, M. H. and Mitra A. (2020b). Molecular characterization and histopathological studies on *Fasciola gigantica* in mithun (*Bos frontalis*). Indian J. Anim. Res. 54(8): 1012-1017.

18. Soulsby, E.J.L. (1986). Helminths, Arthropods and Protozoa of Domesticated Animals, seventh ed. The English Language Book Society. Bailliere and Tindall, London. Pp.1- 809.

Note

Note

ICAR-NATIONAL RESEARCH CENTRE ON MITHUN

MEDZIPHEMA, NAGALAND - 797 106

Website: www. nrcmithun.icar.gov.in

Nrc On Mithun NRCMITHUN Nrc Mithun