Technical Bulletin 2021

Fully Illustrated

FOOT AND MOUTH DISEASE (FMD) IN MITHUN

Clinical Presentation and Management

Vivek Joshi • Vikram R. • J. K. Chamuah
Kezhavituo Vupru • Kobu Khate • M. H. Khan

ICAR-NATIONAL RESEARCH CENTRE ON MITHUN
MEDZIPHEMA, NAGALAND - 797 106
Website: www. nrcmithun.icar.gov.in
Nrc On Mithun NRCMITHUN Nrc Mithun

Technical Bulletin 2021

FOOT AND MOUTH DISEASE (FMD) IN MITHUN

Clinical Presentation and Management

Vivek Joshi, PhD
Scientist, Veterinary Medicine
Animal Health Section

Vikram R., MVSc
Scientist, Animal Reproduction
Animal Physiology & Reproduction Section

J. K. Chamuah, PhD
Scientist, Veterinary Parasitology
Animal Health Section

Kezhavituo Vupru, PhD
Chief Technical Officer
Animal Science

Kobu Khate, PhD
Chief Technical Officer
Animal Science

M. H. Khan, PhD
Principal Scientist, Animal Reproduction
Animal Physiology & Reproduction Section

भाकृअनुप
ICAR

ICAR-NATIONAL RESEARCH CENTRE ON MITHUN
Medziphema, Dimapur, Nagaland- 797106
Website: www.nrcmithun.icar.gov.in
Nrc On Mithun NRCMITHUN Nrc Mithun

I.C.A.R. N.R.C. MITHUN-NAGALAND

Technical Bulletin

August 2021

Publisher:

Director
ICAR-National Research Centre on Mithun
Medziphema, Dimapur, Nagaland 797106

Authors:

Vivek Joshi
Vikram R.
J. K. Chamuah
Kezhavituo Vupru
Kobu Khate
M. H. Khan

Recommended Citation:

Joshi, V., R, Vikram., Chamuah, J. K., Vupru, K., Khate, K. and Khan, M. H. 2021. Foot and Mouth Disease (FMD) in Mithun: Clinical Presentation and Management. Technical Bulletin, ICAR-National Research Centre on Mithun, Nagaland. https://nrcmithun.icar.gov.in.

Design and Printed by:

M/s. Royal Offset Printers, A-89/1, Naraina Industrial Area, Phase-I, New Delhi-110 028

FOREWORD

Among the key challenges faced by mithun *(Bos frontalis)* farmers in the north-eastern hill region (NEHR), the issue of constant resurfacing of devastating foot and mouth disease (FMD) outbreaks is one of the most significant in the short and long term. FMD is considered as a dreaded disease of mithun. At times, a large number of mithuns die due to highly infectious nature of this viral disease and recently, FMD has been postulated as one of the main reasons for the decline in mithun population of Nagaland and Manipur. A range of options exist for the prevention and control of FMD but vaccination with 100 % coverage of free-ranging mithun population is the most vital part of FMD management. Educated mithun farmer with ability to recognize the essential signs of FMD is the most important resource in the prevention and control of FMD. Hence, spreading awareness about FMD among the tribal farmers of NEHR will go a long way in mithun conservation. I am happy to mention that ICAR-National Research Centre on Mithun has been regularly organizing a large number of outreach programmes in four mithun rearing states to raise awareness about the prevention, control and eradication of FMD.

Mithun or *Gayal* or *Eso* or *Sial* or *Sandong* or *Wei* is a rare bovine species exclusively found in the NEHR and plays a major role in the tribal economy. It provides multifaceted contributions to the tribal livelihoods as mithun possesses a great potential for milk, hide (leather) and draft power, apart from organic meat. In general, mithun husbandry is a low-investment and high-profit venture. However, FMD is one of the significant barriers to sustainable economic growth of mithun husbandry. FMD causes direct losses to mithun farmers, which are usually associated with large number of mortalities in young mithun calves and reduced reproductive efficiency in adult mithuns. The impact of FMD on mithun reproduction, particularly in free-range system, is non-quantifiable

and thus, considered as an invisible loss. Despite the dreaded nature of FMD, vaccination is not practiced by the majority of farmers due to their negligence, ignorance and superstitions about vaccination.

In the present scenario, I believe that this technical bulletin shall provide stakeholders with a common understanding of the disease agent and the ways and means to control FMD in mithun. It is worthwhile to compliment all the authors for their relentless efforts to include all the valuable information in this bulletin. I am confident that this document is necessary and shall prove to be useful for the mithun rearing tribal communities of NEHR and veterinary professionals.

Date: 25 August 2021
Medziphema, Nagaland

(M. H. Khan)
Director (Acting)

PREFACE

The purpose of this Technical Bulletin is to provide complete information about the importance of foot and mouth disease (FMD) in mithun *(Bos frontalis)*, its economic impact, transmission, diagnosis, treatment and prevention & control strategies. Its aim is to describe and disseminate awareness about standard procedures, such as mass vaccination with recommended vaccines, for the prevention of frequent FMD outbreaks. This should promote improvements in mithun health management and mitigate fatalities across the north-eastern hill region (NEHR). The bulk of this document concentrates on the manifestations and management of FMD in mithun that have been well-illustrated in clear images, not burdened with unnecessary details.

Foot and mouth disease is a notifiable and highly contagious viral disease of mithun. It is an OIE (World Organisation for Animal Health) listed transboundary disease, endemic in the NEHR. It is well known that the clinical presentation in mithun is identical to FMD in cattle and it is presumed that cattle (Tho-Tho cattle in Nagaland) and pigs play a significant role in the maintenance and spread of FMD infection to mithun. Hence, it is imperative to synchronously vaccinate mithuns along with cattle/pigs for effective control and eradication of FMD. mithun inhabits dense forests and this geographical constraint hinders the vaccination of major part of mithun population, making them more susceptible to FMD. Barbed fencing or bio-fencing of the community forest area is an effective strategy to prevent interspecies mingling and check spread of FMD from wildlife/livestock to mithun. At present, ICAR-National Research Centre on Mithun is making every effort to provide fencing inputs such as barbed wires and technical back-up to the mithun farmers.

We strongly believe that it was a long-felt need to provide a Technical Bulletin with one-stop information on FMD in mithun. The importance is given to timely detection of outbreaks by the mithun handlers, based on essential signs of FMD and prevention and control measures. Outside experts were also consulted before finalizing this bulletin. We believe that continual revision is desirable in such a shifting field and ICAR-National Research Centre on Mithun shall leave no stones unturned to issue an updated version of the Bulletin, if deemed necessary. We extend our most sincere gratitude to all the contributors who directly or indirectly helped and made it possible to produce this bulletin. We hope that this document shall be beneficial to all the stakeholders, veterinary professionals and readers engaged in mithun husbandry and other allied livestock sectors.

Date: 25 August 2021
Medziphema, Nagaland

Authors

CONTENTS

1 INTRODUCTION

Mithun *(Bos frontalis)*: A Gifted Bioresource

Mithun or *Gayal* or *Cattle of Mountain* is a rare bovine species mainly found in forests of northeastern hilly states at an altitude of 300-3000 m. It is exclusively reared by indigenous tribes of Arunachal Pradesh, Nagaland, Mizoram and Manipur. Mithun rearing is an important activity intrinsically linked to sustainable livelihood in northeast India. In India, mithun is considered not just an animal but a symbol of prestige and prosperity. It plays a central role in socio-economic and cultural life of tribal people. The origin of mithun is quite complex and ambiguous and it is phylogenetically distinct from other *Bos* species. Recently, a study conducted at ICAR-National Research Centre on mithun, Nagaland has revealed a common origin of mithun and gaur from an ancient and extinct bovine species. In Arunachal Pradesh, mithun is called *'Eso'* or *'Hoho'* or *'Sebe'*, the Mizos call it *'Sial'*, it is called *'Sandong'* in Manipur and *'Wei'* and *'Seizang'* in Naga tribes.

Mithun is a mammalian species belonging to family bovidae and order ungulate (hoofed mammal). This large herbivore is capable of browsing efficiently even in steep hilly slopes (Fig. 1). mithun is a selective browser and travels for long distance in forests in search of fodder. In general, mithun is a medium to large sized ruminant, characterized by a jet black body with ash colored forehead and white stockings in the legs. The hump is absent and its tail and legs are smaller in comparison to cattle. The calves are golden yellow/brown in color (Fig. 2), however, as the age advances, color changes to jet black (Fig. 3). The average body weight of adult mithun aged 4-5 years is usually 400-500 kg. It is mainly reared for meat purpose. The gestation length is 270-290 days and normally, it gives birth to one calf at a time.

Since time immemorial, the farmers rear mithuns in forests under free grazing system and in the majority of cases, they do not provide scientific health care to mithun in free-range forest ecosystem. Currently, total mithun population in the country is 3.8 lakhs. The highest population of mithun is found in Arunachal Pradesh which constitutes about 90 % of its total population, followed by Nagaland (5.98 %), Manipur (2.36 %) and Mizoram (1.02 %). According to 20th Livestock Census (2019), mithun population has shown an overall increase of 30.6%, however, Nagaland and Manipur exhibited a decline of 33.6 % and 10.5 % in their mithun population, respectively.

Fig. 1 Free-ranging mithun in steep hilly terrain

Fig. 2 Young mithun calves

Fig. 3 Adult mithun bull

At present, with a narrow geographic range, small population and inadequate health care services leading to frequent outbreaks of diseases such as foot and mouth disease, mithun is considered as species vulnerable to extinction.

Foot and Mouth Disease (FMD) in Mithun

Mithun rearing in northeast India is confronted with different hassles including the wide prevalence of FMD. After the eradication of rinderpest, FMD has emerged as the single most economically devastating disease among mithuns in the northeastern states. It is commonly observed that mithun is comparatively more susceptible to FMD than other livestock species. The morbidity of the disease is usually > 60 % with reports of high mortality. It is a well known fact that FMD stands as a barrier to consideration of export of mithun meat. Presently, the disease is a major threat to mithun population which may hamper meat production and cause local food insecurity in the northeastern region. Furthermore, it has a widespread impact on reproduction and draught ability of mithun.

Foot and mouth disease or FMD or Aphthous fever is a notifiable and highly contagious viral disease of domestic and wild cloven footed animals of the order Artiodactyla, including mithun. It is an OIE listed transboundary disease, associated with huge economic losses to the livestock industry worldwide. The disease is endemic in parts of Asia including northeast India and considered a dreaded disease in mithun. It is well known that FMD in mithun is primarily spread through inhalation of virus aerosols. The clinical presentation in mithun is identical to FMD in cattle, including the post-mortem findings. The typical clinical sign is the development of vesicles on the muzzle, tongue, lips and in the interdigital space of mithun. During outbreaks, FMD is readily manifested as a clinically acute and vesicular disease in mithun. However, preventive vaccination is an effective strategy to reduce the outbreaks of FMD in mithun. The virus responsible for FMD is an aphthovirus, foot and mouth disease virus, which is the oldest known animal virus.

In mithun, FMD is caused by serotypes O, A, and Asia-1, of which serotype O is primarily responsible for most of the outbreaks. These viruses isolated from mithun were genetically similar to those causing FMD in domestic cattle suggesting a situation of virus sharing between mithun and domestic cattle. Thus, there is an urgent need to synchronously vaccinate mithuns along with cattle for the effective control and eradication of the disease.

Status of FMD Outbreaks in Northeast India

Foot and mouth disease outbreaks are common in mithun during late monsoon and winter seasons. As the northeastern region of India shares international borders with Bangladesh, China, Myanmar and Nepal, human movement, inter-border crossing of animals for better grazing, animal products, wind and water may lead to the outbreak of FMD in the mithun population. During 1974 to 2004, a total of 12 outbreaks of FMD were recorded in mithun by AICRP on FMD, Guwahati. In Arunachal Pradesh and Nagaland, the mortality rate was 35.47-52.42 % and 33.87-53.57 %, respectively. Over the past decade (2009-2019), there have been 120 confirmed FMD outbreaks in four mithun rearing states (Arunachal Pradesh, Nagaland, Manipur, Mizoram) of northeastern hill region (NEHR) (Fig. 4). The predominant serotype causing outbreaks was 'O' followed by 'Asia 1' and 'A' (Table 1).

During 2009-10, a total of 19 outbreaks of FMD in mithun were recorded in various parts of Arunachal Pradesh while Nagaland was hit by 8 severe outbreaks of FMD in mithun between 2006 and 2014. In 2018, two severe FMD outbreaks were reported in Nagaland which affected as high as 3205 mithun and led to 101 mortalities. The exact pathogenesis of FMD in mithun has not been studied in detail and a focused study is needed to pave the way for developing mithun-specific standard operation protocols (SOP) for effective monitoring and control of FMD infection. A better understanding of

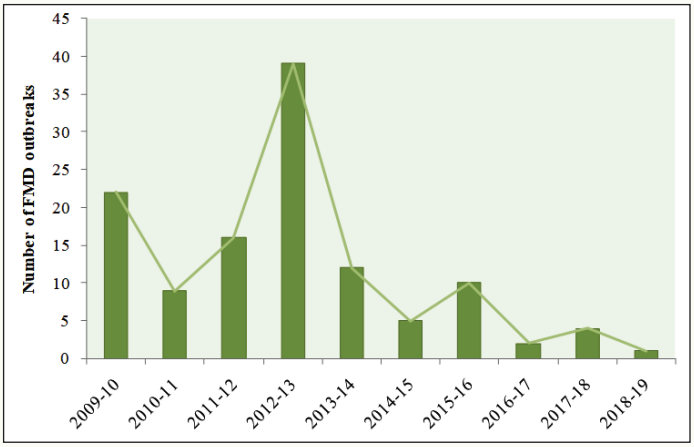

Fig. 4 Trend of FMD outbreaks in mithun in NEHR (*over the last decade*)

the disease epidemiology in mithun is required for the planned eradication of FMD from the northeast India. The rapid and optimized diagnostic techniques will prove useful in this direction.

Table 1: List of serotypes involved in FMD outbreaks in mithun (*over the last decade*)

Year of FMD outbreak	Serotype involved
2009-10	O
2010-11	O, Asia-1
2011-12	O, A
2012-13	O, Asia-1
2013-14	O, A
2014-15	O
2015-16	O, Asia-1
2016-17	O
2017-18	O
2018-19	O

Risk Factors for FMD Outbreaks in Mithun

The common predisposing and precipitating factors significantly associated with FMD outbreaks in mithun are (Fig. 5):

1. Lack of routine vaccination and mass (100 %) vaccination campaigns.
2. Inadequate maintenance of cold chain (2-8 °C) facilities during the transport, storage and handling of FMD vaccines.
3. Improper landmarking or administration of FMD vaccine by non-official veterinary personnel.
4. Bringing unvaccinated mithuns to 'mithun melas or fairs'.
5. Acute scarcity of green fodder during lean period or dry season (November to March), resulting in loss of body weight and increased susceptibility to FMD.
6. Transboundary movement and mixing with cattle and FMD-susceptible wild animals.
7. Delayed and improper disposal of carcasses of mithuns.
8. Mithun behavior : Mithuns live in forests in groups where they recognize their kith and kin by smelling the muzzle and this behavioral attribute predisposes them to FMD.

9. Purchasing a new mithun without following quarantine protocol.
10. In earlier days, mithuns feeding on wild ginseng leaves used to have strong immunity but nowadays, native people harvest ginseng for commercial use and thus, there is scarcity of this immunostimulant herb for mithun in the forests.

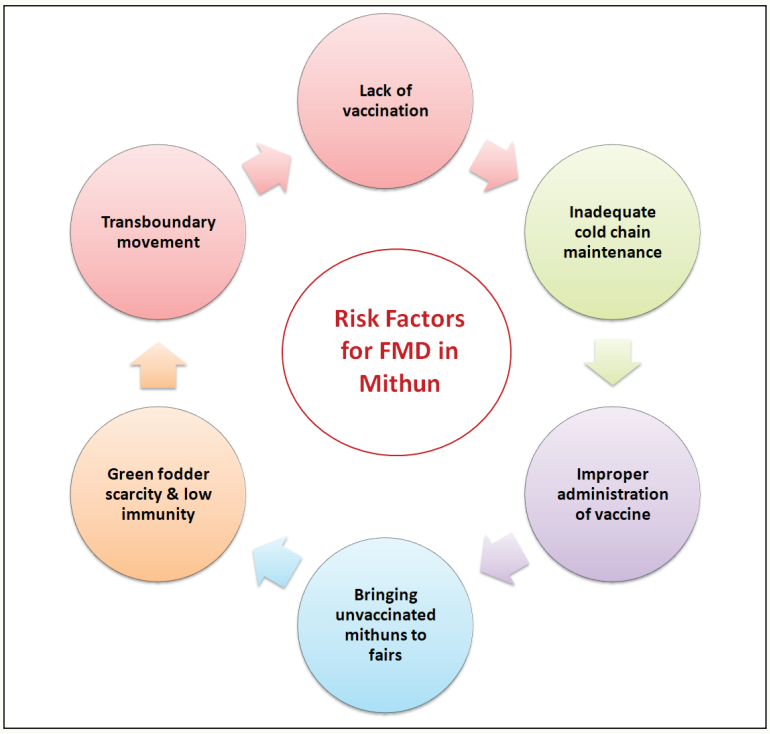

Fig. 5: Illustration of risk factors for FMD in mithun

QUICK SUMMARY

- Mithun is comparatively more susceptible to FMD than other livestock species.
- In mithun, FMD outbreaks are common during late monsoon and winter seasons.
- There is an urgent need to synchronously vaccinate mithuns along with cattle for effective control and planned eradication of FMD.
- Lack of mass (100 %) vaccination is the commonest risk factor associated with FMD outbreaks in mithun.

2 PROPERTIES OF FOOT AND MOUTH DISEASE VIRUS

Foot and mouth disease virus (FMDV) is the smallest animal virus belonging to the genus *Aphthovirus* and family Picornaviridae. It is epitheliotropic in nature and possesses 7 serotypes *viz.* A, O, C, Asia 1, and SAT (Southern African Territories) 1, 2, and 3. In mithun, the common etiology of FMD is serotype O, followed by Asia 1. However, in early 2021, serotype A was confirmed as a cause of FMD outbreak in semi-intensively reared mithuns at ICAR-National Research Centre on mithun, Medziphema, Nagaland. According to the previous reports, genetic characterization of FMDV revealed the prevalence of PanAsia lineage of serotype O virus in mithuns as observed with cattle and buffaloes. The virus infecting mithuns also exhibited a close antigenic relationship with in-use bovine vaccine virus, indicating appropriateness and usefulness of mithun vaccination against FMD employing the current bovine vaccine.

Like other picornaviruses, FMDV has a positive-sense RNA genome and the RNA sequence is about 8500 nucleotides long. The structural proteins of the FMDV termed VP1, VP2, and VP3 are exposed on its external surface while VP4 remains internal. The capsid of FMDV protects the viral genome and facilitates virus entry into the cells by binding to the specific cell surface receptors. After internalization of FMDV into the mammalian cells, its RNA genome is released into the cytoplasm, translated for protein synthesis and then, replicated. The new virus particles are produced by the packaging of positive sense RNA by the capsid proteins. Within a few hours, several thousands of new FMDV particles are formed within an infected mammalian cell.

Foot and mouth disease virus is moderately resistant in the environment and can survive for days to months in different animal products including meat and meat by-products. It can remain viable on hay or straw bedding for at least 200 days, in fecal slurry for 6 months in winter, in urine for up to 39 days, in soil for 3 (summer) to 28 (winter) days and in dry fecal matter for 2 weeks in summer. The virus is found in the breath, saliva, faeces, urine, milk, semen (before onset of clinical signs), meat and meat by-products (if pH has not declined to <6) of incubating and clinically infected animals. Generally, FMDV is stable at pH range of 6-9 and quickly inactivated outside this range. During rigor mortis, pH of bone marrow, lymph nodes, certain organs and offals does not decline, therefore, FMDV can survive in them for an extended period of time and may lead to new outbreaks if animal carcasses are not effectively disposed. The proper disposal of carcasses and

wastes following FMD outbreak can prevent its further spread.

The virus responsible for FMD is readily inactivated by desiccation and at temperatures >56 °C, however the virus may survive pasteurization at 72 °C for 15 seconds for a significant time period when coupled with animal protein such as in infected milk. The virus is resistant to lipid solvents such as alcohol, ether and chloroform. The most effective disinfectants against FMDV are sodium hydroxide (2 %), sodium carbonate/soda ash (4 %), citric acid (0.2 %) and acetic acid (vinegar). The disinfectants such as phenols, hypochlorite, iodophors and quaternary ammonium compounds are less efficient, particularly in the presence of organic matter.

It is noteworthy to mention that FMDV has high agroterrorism potential on account of its contagious nature, long-distance transmissibility through wind and by fomites, and the ability to cause economic havoc.

QUICK SUMMARY

- FMDV is found in breath, saliva, nasal fluid, faeces, urine, milk, semen, meat and meat by-products of infected animals and its serotype O commonly causes FMD outbreaks in mithun.
- In mithun, there is prevalence of PanAsia lineage of serotype O virus as observed with cattle and buffaloes.
- FMDV infecting mithun antigenically resembles bovine vaccine virus, indicating correctness of mithun vaccination against FMD, using current bovine vaccine.
- The most effective disinfectants against FMDV are 2 % sodium hydroxide, 4 % sodium carbonate/soda ash, 0.2 % citric acid and acetic acid/vinegar.

3 MODE OF TRANSMISSION OF FMD IN MITHUN

A variety of mechanisms contributes to the transmission of FMD in mithun (Fig. 6). However, direct contact, through inhalation of virus aerosols when mithun coughs or sneezes, is understood to be the primary mechanism of spread of FMD within mithun herds. Being a free-range animal, mithun lives in forests in groups where it recognizes its kith and kin by smelling the muzzle and this in turn triggers rapid spread of FMD in mithun population. It is also believed that cattle (Tho-Tho cattle in Nagaland) and pigs play a significant role in the spread of FMD infection to mithun.

During acute infection, FMD transmission is facilitated by shedding of virus in fluid of ruptured vesicles and excretions and secretions of the body. The virus can enter the host via inhalation, ingestion or through skin wounds and mucous membranes. In endemic settings, the spread of FMD virus to a new host occurs by different modes which are categorized as:

Direct contact

The disease is spread by direct contact between infected and susceptible mithuns such as when a healthy mithun touches or licks a sick mithun. It is commonly observed in mithun that licking is one way they bond and show affection and during outbreak, this licking behavior stimulates faster spread of FMD in mithun. In semi-intensive farm setting, it can also spread when a healthy mithun eats from a feed trough where an infected mithun has eaten or drooled its saliva (oral route). Moreover, when an infected mithun coughs or sneezes, the virus can spread to in-contact or nearby susceptible mithuns (aerosol/respiratory route). Transmission through aerosol route requires a very low dose of virus while a higher dose is required for spread through oral route and abrasions.

Indirect contact

Indirect transmission routes play a central role in the spread of FMDV. The susceptible mithuns may be infected by indirect contact with bodily secretions or excretions from infected mithuns, including milk and semen. Like cattle, there is every likelihood of shedding of FMD virus in the milk of mithun cows and thus, virus transmission to calf is likely via ingestion of contaminated milk. In semi-

intensively reared mithuns, artificial insemination with contaminated semen may spread the disease.

Animate vectors

Like cattle, humans, including animal handlers, visitors and veterinarians, may serve as mechanical vectors of FMD transmission in mithun. FMDV can be carried on the clothing, shoes, skin and even the respiratory tract/nasal passages of people. However, FMD is not considered a public health problem and a thorough shower and change of clothing keep the people away from infection.

Inanimate vectors (fomites)

Similar to cattle, vehicles, implements, fodders, equipments etc. may spread FMD infection in mithun population.

Airborne transmission

As the northeastern states of India share international borders with Bangladesh, China, Myanmar and Nepal, long distance airborne transmission of FMDV has always been considered as a suspected risk factor for FMD outbreak in mithun population. This mode of transmission is dependent on wind direction, relative humidity, temperature and geographical topography.

Transmission by rodents and birds

Like cattle, the spread of virus by rodents and birds looks very unlikely or negligible in mithun.

In most instances in cattle, the outcome of FMD is asymptomatic carrier state. Therefore, it may be postulated that cattle serve as the carriers of FMD virus, maintain it in their esophageal-pharyngeal fluid, periodically shed it and lead to FMD outbreak in mithun.

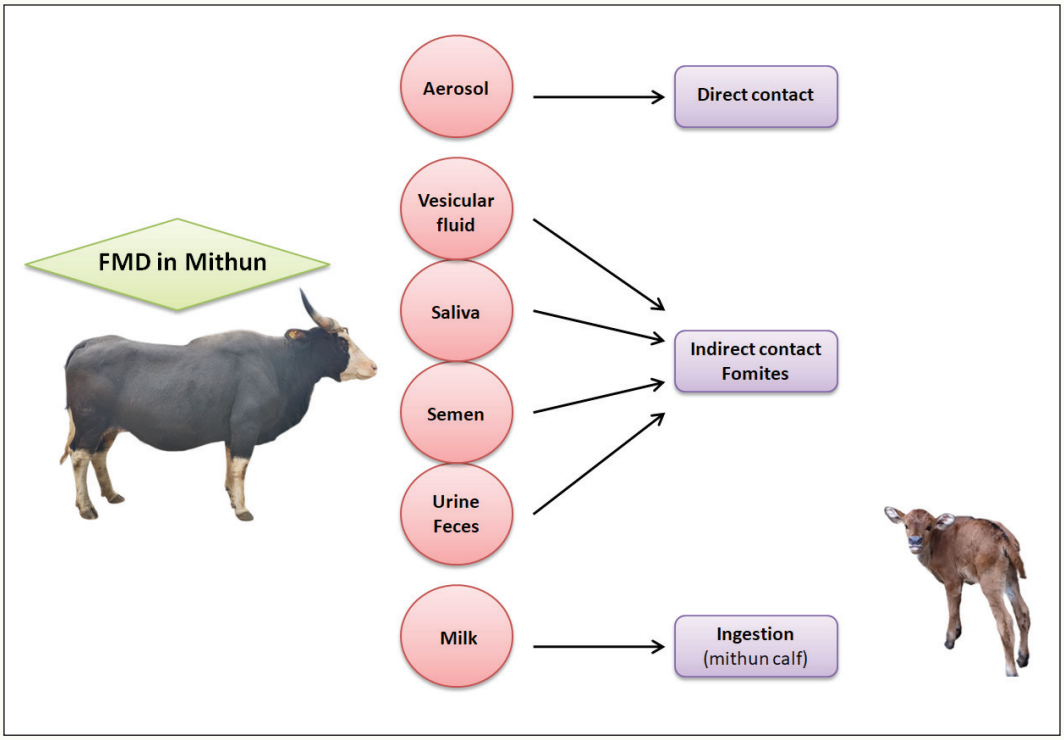

Fig. 6 Probable modes of transmission of FMD in mithun

QUICK SUMMARY

- The direct contact, through inhalation of virus aerosols, is the primary mechanism of spread of FMD within mithun herds.
- Mithuns live in forests in groups where they recognize their kith and kin by smelling the muzzle and licking, this behavior triggers rapid spread of FMD in mithun during any outbreak.
- It is hypothesized that cattle and pigs play a pivotal role in the maintenance of virus and spread of FMD infection to mithun.
- In mithun, airborne transmission of virus might be a suspected risk factor for FMD outbreak.

4 CLINICAL SIGNS OF FMD IN MITHUN

Clinical Findings

The clinical signs of FMD in mithun are similar to domestic cattle and limited to foot and mouth. Unlike cattle, lesions of the mammary gland and teats are rarely observed in mithun. All three serotypes of FMD virus, i.e. O, A and Asia 1, prevalent in mithun population, cause similar signs and symptoms. Mithuns of all age groups are susceptible to FMD infection, however the clinical signs and sequelae might vary. The clinical signs can range from an inapparent or mild illness to severe or fatal infection. The severity of clinical signs may vary with the age and immune status of the animal, virus strain and the exposure dose. The incubation period often lie in the range of 2-14 days. FMD is a highly contagious disease with 60-100 % morbidity in a susceptible non-vaccinated mithun population. Like cattle, FMD is fatal in young mithun calves with significant mortality, however case fatality rate is much lower in adults. In uncomplicated cases, FMD is generally self-limiting and may recover within 2 weeks. Mithuns that survive often suffer from weakness, debilitation, chronic lameness, reproductive disorders and exhibit poor weight gain leading to severe loss of meat production.

In mithun, the first observed clinical signs are dullness/depression, inappetance to anorexia and high fever/pyrexia (104-106 °C) which usually last up to 2-4 days. These are indicative of viremia before the onset of development of characteristic vesicular lesions (Fig. 7). Vesicle formation results in profuse foamy salivation associated with constant drooling of ropy saliva from the mouth (Fig. 8 & 9), audible lip-smacking sound, constant feet-licking and stamping of feet followed by lameness. Later, these vesicles rupture and leave behind erosions/ulcers (Fig. 10-14). In adult mithuns, small fluid-filled vesicles/blisters are formed on the tongue, muzzle, palate, dental pad, coronary band, bulb of the heels and in the interdigital space and cleft (Fig. 15-18). Bloody nasal discharge from 3rd to 4th day is a distinct feature of mithun FMD (Fig. 19).

In the forests, free-ranging mithuns affected with oral ulcers tend to starve themselves due to inability to ingest feed and fodder. Eventually, starvation and inadequate veterinary care to FMD infected mithuns living in the inaccessible interior of wild forests lead to death. If these erosions are not well managed, secondary complications occur. Maggot wound or wound myiasis is the most common and serious complication of FMD in free-ranging mithuns (Fig. 20). Here, maggots (dipteran larvae) infest the nasal and oral cavities as well as the hooves of

mithun and feed on the tissues causing restlessness, traumatic injuries, difficulty in ingestion, reduction in meat production, permanent lameness and ultimately, death.

In semi-intensive farm setting, secondary bacterial infection of ruptured blisters on the feet can cause extreme lameness and the affected mithun keeps lying down with reluctance to rise and move. Proper treatment and care can reduce the morbidity rate in adult mithuns, with recovery occurring within 2-3 weeks. However, when mithun calves are infected, mortality rates can be high due to multifocal myocarditis. The health of young mithun calves may be compromised due to lack of milk from infected dams. Other important complication of FMD includes abortion in pregnant mithun cows.

(a) (b)

Fig. 7 Multiple vesicles on (a) muzzle & (b) ventral surface of tongue

(a) (b) (c)

(d)

(e)

Fig. 8 (a)-(e) Profuse foamy salivation

(a)

(b)

Fig. 9 (a) & (b) Drooling of ropy saliva & Erosion of muzzle

(a)

(b)

Fig. 10 (a) & (b) Ruptured oral vesicles

Fig. 11 Ruputured vesicle in nasal cavity

Fig. 12 Erosion of dental pad

Fig. 13 Ruptured vesicle of palate



Fig. 14 Ruptured vesicles on tongue

(a) (b)

Fig. 15 (a) & (b) Foot lesions

Fig. 16 Erosion in interdigital space

Fig. 17 Erosion of heel bulbs

(a) (b)

Fig. 18 (a) & (b) Foot lesions & Lameness

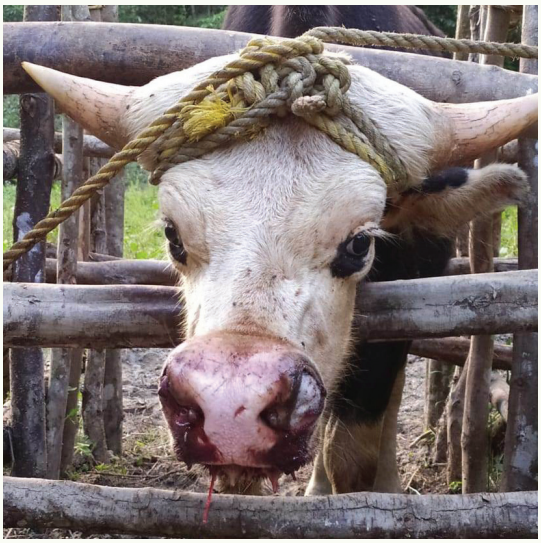

Fig. 19 Bloody discharge from nostrils

Fig. 20 Maggot wound in nasal cavities

Necropsy Findings

In adult mithuns, no significant postmortem lesions are observed. However, the postmortem examination of young mithuns dying from FMD reveals significant gross lesions in the heart. A soft and flabby heart with greyish white streaks on the epicardium i.e. 'tiger heart' is pathognomic gross lesion of FMD in young mithun calves (Fig. 21). These lesions appear due to focal degeneration and necrosis of cardiac muscle fibers. Other sporadic lesions are intestinal congestion (Fig. 22) and hemorrhages on the margins of spleen (Fig. 23) in young calves while in adults, hemorrhages in the kidney are reported.

(a)

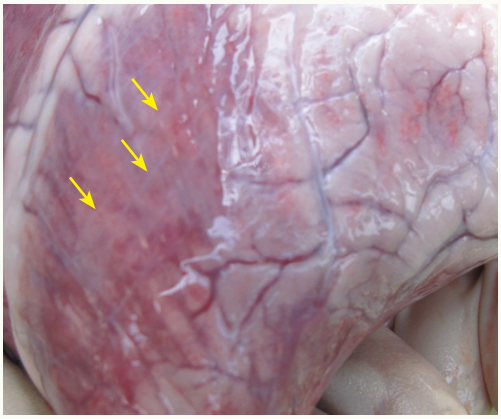

(b)

Fig. 21 (a) & (b) "Tiger-heart" appearance in mithun calf

Fig. 22 Congested gut wall of mithun calf

Fig. 23 Hemorrhages on spleen of mithun calf

QUICK SUMMARY

- In adult mithun, high fever (104-106 °C), vesicles on the tongue, muzzle, dental pad and in interdigital space/cleft and drooling of ropy saliva are predominant signs of FMD.
- In young mithun calves dying from FMD, 'tiger heart' is the grossly visible pathognomic lesion.
- During FMD outbreak, inadequate veterinary care to infected mithuns living in the inaccessible interior of wild forests frequently leads to death.
- Maggot wound is the most common and serious complication of FMD in free-ranging mithuns, which if left untreated, may result into starvation & lameness and progress to death.

5 PUBLIC HEALTH RISK DUE TO FMD IN MITHUN

In earlier days, FMD was not recognised as a zoonotic disease. It was not readily transmissible to humans and not considered a public health problem. It was postulated that people including mithun farmers and veterinarians can only act as mechanical vectors of FMD by carrying virus on their clothing, shoes or skin.

At present, it is a well proven fact that FMD is a very mild zoonotic disease and humans are only rarely infected as FMD virus crosses the species barrier with difficulty and with little effect. Only a few benign cases of FMD infection in humans associated with FMD in cattle and buffaloes have been reported, none requiring admission to hospital for treatment. However, to date, no case of human infection of FMD contracted from mithun has been reported or documented.

Humans can be very mildly infected with FMD by direct contact with infected animals, ingestion of raw milk, unpasteurized dairy products or undercooked meat from infected animals, but this is extremely rare. Other sporadic cases might be caused by laboratory accidents during handling of FMD virus. FMD cannot readily spread to humans by eating infected meat except in the mouth before swallowing of meat, because the virus is sensitive to stomach acid.

The virus can enter the human body through traumatized skin, wound or mucous membrane. There is no human to human transmission of FMD. The mithun farmers/owners/handlers, veterinarians and laboratory workers are at risk of getting the disease, if good personal hygienic practices including standard hand washing practices before and after handling their mithuns and biosafety measures are not followed. The incubation period in humans is usually 2-6 days. Human infection is often characterised by mild symptoms such as blisters on the hands/ fingers and in the mouth, fever up to 103 °C, mild headache, malaise and sore throat. Mostly, serotype O causes FMD infection in humans.

The transmission of FMD infection from mithun to humans is extremely rare but it is always advisable to follow good hygiene measures after handling mithuns, particularly during FMD outbreak. The FMD virus can survive for long periods in fresh, undercooked, cured and smoked meat and in inadequately pasteurized dairy products, therefore, thorough cooking (at least 20 minutes at 80 °C) and adequate pasteurization are essential to make the meat and milk items safe for consumption.

QUICK SUMMARY

- FMD is a very mild zoonotic disease and humans are only extremely rarely infected with mild symptoms such as blisters on the fingers and mild headache.
- To date, no case of mithun to human FMD transmission has been reported.
- The mithun farmers/owners/handlers and veterinarians are at risk of getting FMD by direct contact with infected mithuns, particularly during disease outbreak.
- Following standard hand washing practices before and after handling mithuns, thorough cooking of meat and adequate pasteurization of milk are essential for keeping FMD infection in humans at bay.

6 IMPACT OF FMD ON MITHUN FARMING

Mithun plays a central role in socio-economic and cultural life of tribal people of Nagaland, Arunachal Pradesh, Manipur and Mizoram. Being considered a ceremonial animal, mithun is slaughtered for high quality meat during marriage ceremonies, religious festivals and community feasts. It possesses immense potential for use as draught purpose animal in the hilly tracts. mithun is regarded as a last resort of money and sold by poor farmers at the time of adversity to fulfill money requirement for education of children and health emergencies. It is also used for barter trade purpose apart from paying fine, ransom and price of bride by groom's family (bridal gift). Thus, mithun farming is the main source of livelihood for rural farmers in northeastern states of India. There has been growing concern that if the trend of resurfacing of FMD outbreaks in mithun continues, in very near future deaths of mithun may increase many folds leading to economic havoc in mithun farming.

The economic losses incurred by FMD outbreaks in mithun can be divided into two categories:

Direct economic impact of FMD refers to the losses caused by disrupted production and quality of organic meat, high mortality in young mithuns and reproductive

1. Direct Impact of FMD

Visible Losses

- Loss of meat production
- Lower weight gains
- Death of young mithuns
- Abortions/Still births

Invisible losses

- Lower fertility/Infertility in recovered mithuns
- Change in the mithun herd structure

disorders including abortions, still birth in pregnant mithun cows and infertility in the recovered mithun bulls/cows.

Indirect economic impact of FMD refers to long-term consequential losses which occur in the form of business interruption and losses associated with high costs of execution of FMD control program and repopulation costs.

2. Indirect Impact of FMD

Additional Costs

- Diagnostic tests
- Purchase of vaccines
- Vaccine delivery
- Monitoring of mithuns

Revenue Loss

- Denied access to markets for sale of mithun meat

QUICK SUMMARY

- In northeastern states, the continuously resurfacing outbreaks of FMD can result into economic havoc in mithun farming.
- FMD outbreaks can result into direct or indirect economic losses to the mithun farmers.

7 IMPACT OF FMD ON REPRODUCTION IN MITHUN

The impact of FMD on the reproduction in mithun is considered as an invisible loss as the effects are unmeasurable, particularly in the free-range system where there are minimum chances to control the rapid spread of disease. This disease results in a significant reduction in feed intake affecting the growth rates and in turn fertility in both male and female mithun. The induced inflammatory reaction affects the endocrine system resulting in no or poor estrus (heat) expression, embryonic death, or conception failure. Pyrexia (fever) can impair pregnancy maintenance and induce abortion in pregnant animals. The bulls affected will be weak due to the inflammatory and acute-phase reactions and semen quality will be impaired leading to failure of conception.

FMD affects Reproductive Performance of Mithun Cows

The FMD induced inflammatory or acute phase reaction has a direct impact on the female reproductive system thus reducing the reproductive efficiency of the herd. The FMD effects can include irregularity of estrus/heat, impaired ovarian function, failure of conception or increased abortion rate thus extending calving interval (Fig. 24).

1. Impaired ovarian activity

Ovarian inactivity is the most predominant cause of reproductive failure in FMD infected mithun cows. The infected animals will not appear in the heat for a longer duration post-infection. In some animals, the intensity of heat expression will be low or animals will be in silent heat. Rectal palpation in these animals shows smooth bilateral ovaries with no eggs (Graafian follicles) or corpora lutea. It is probably due to the direct impact on the ovarian tissue or indirectly on the endocrine system affecting the growth and maturation of the egg. The stress condition (oxidative stress) in affected animals is also a major factor responsible for impaired ovarian function.

2. Abortion

It is reported that this virus causes a transplacental infection which can impair pregnancy maintenance and induce abortion. Abortion can occur at any point of

time during pregnancy. However, early pregnancy loss is 3-4 fold times increased particularly during the first trimester of gestation which goes unnoticed is a major reproductive challenge. The abortion is due to the inflammatory and acute-phase reactions induced by the FMD. As mithun is reared in the free-range system, the loss of appetite, as well as the energy to move and cannot access the feed due to fever and oxidative stress, is largely responsible for abortion.

3. Retained placenta

Retained placenta before and after foot and mouth disease may not be significant, but during FMD outbreak the retained placenta condition is normal.

4. Conception failure

It will be high in the period after foot and mouth disease outbreak compared to before disease. This is due to failure in ovulation or delayed ovulation or improper endocrine function in female animals. Additionally, bulls will be reluctant to mate due to weakness/lameness or poor semen quality during and after the FMD.

5. Increased age at first calving

In heifers, the age at first calving is higher in infected animals. This may be due to reduced feed intake and growth rates resulting in the poor quality dominant follicle, corpus luteum, and subsequent conception failure. Mithun heifers that are ill by FMD during the rearing period calve later than those not ill during the rearing period.

FMD affects Reproductive Performance of Mithun Bulls

Mithun breeding bulls are very important in the herd as they are considered as "half the herd". Once the bull is infected with the FMD virus, the oral lesions and the increased temperature contribute to the decreased feed intake in turn leading to weakness. Mithun bulls can develop vesicles and blisters on the scrotum. The lesions present in between and above hoof regions cause lameness and the bull will be unable to mount or mate the mithun cows. FMD is transmitted through semen and semen quality will also be affected due to temperature rise (Fig. 25).

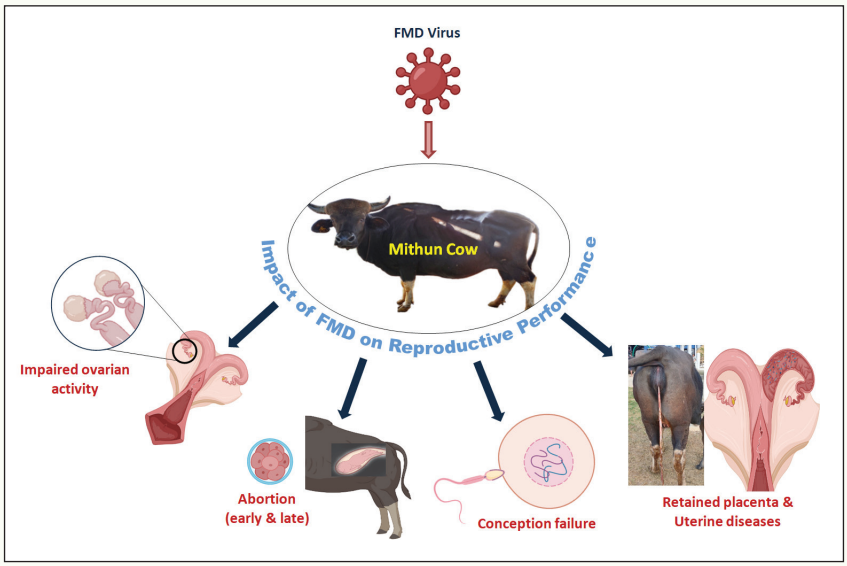

Fig. 24 Impact of FMD on reproductive performance of mithun cow

1. Lameness

Lesions probably are common on the feet and in the mouth. Extensive lesions on the coronary band may lead to sloughing of the hoof and lameness. Foot lesions may involve one or more of the feet. Vesicles usually rupture within 24 hours and reveal hyperemia and hemorrhage on the underlying tissue. Uncomplicated lesions usually heal within two weeks. If the bacterial infection occurs it leads to lameness for long period. Due to the lameness animal cannot mount on the estrus female even after the disease is completely cured.

2. Transmission of the virus through semen

- FMD virus is easily transmitted through semen.
- The virus is detected in semen up to 4 days before the development of clinical signs.
- Mithun cows will be infected with FMD by mating from infected bulls or artificially inseminated with infected semen.
- FMD virus has been found in semen as long as 42 days from the time of contact exposure.

3. Poor semen quality

Febrile reaction due to FMD results in very mild testicular degeneration. During

FMD and post FMD for a certain period there is a significant reduction in the sperm motility, live sperm count, percent of cold shock-resistant sperms, and increase in sperm abnormalities of mithun bull semen. The significant rise in body and testes temperature causes derangement in epididymal functions and sperm production. The temperature rise could be responsible for sperm abnormalities. FMD recovered bull should not be used for mating or semen collection until the normal fertility of sperm is restored (i.e. 2 to 3 months) to avoid the conception failure.

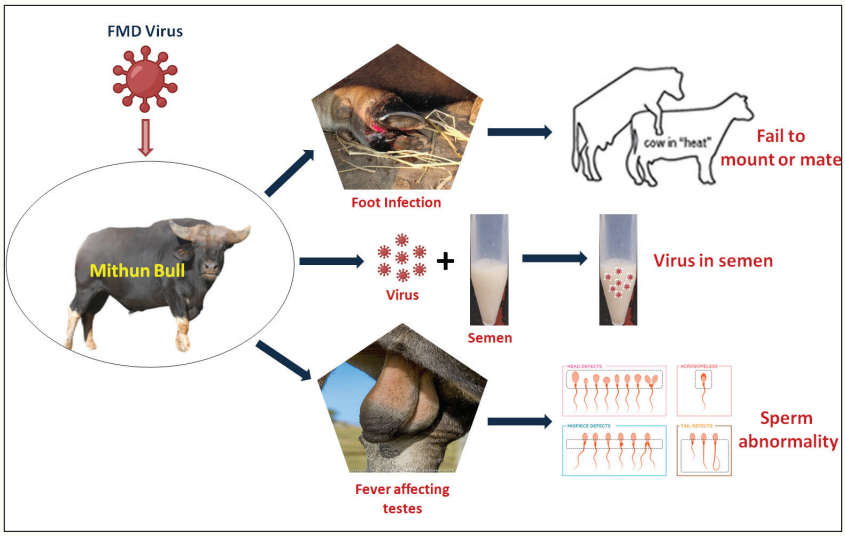

Fig. 25: Impact of FMD on reproductive performance of mithun bull

QUICK SUMMARY

- The impact of FMD on mithun reproduction is non-quantifiable and thus, considered as an invisible loss, particularly in the free-range system.
- In female mithun reproduction, FMD can cause irregularity of estrus/heat, impaired ovarian function, conception failure, increased abortion rate, retention of placenta and extended calving interval.
- In male mithun reproduction, FMD can cause lameness and inability to mount on the estrus female and lead to poor semen quality and sperm production.
- FMD virus is easily transmitted through semen of mithun and thus, mating with infected bulls or artificial insemination (AI) using infected semen can spread the disease.

8 DIAGNOSIS OF FMD IN MITHUN

In general, FMD can be controlled by regular vaccination of susceptible animals and slaughtering of infected animals. However, no country is considered safe because of the highly contagious nature and rapid spread of FMD infection. In 2019, the government of India launched the National Animal Disease Control Programme (NADCP) for eradicating FMD and brucellosis by vaccinating 100 % susceptible livestock population by 2030. The irony is that mithun has not been included in this scheme and 100 % vaccination coverage in mithun is also not possible as the majority of mithun population lives in forests. Therefore, early recognition of clinical signs and rapid laboratory diagnosis is of utmost importance to check the spread of FMD in mithun. The suspected cases of FMD in mithun are confirmed either by detecting the viral antigen/genome or antibodies. Different serological tests and molecular techniques such as polymerase chain reaction (PCR) are useful in rapid and precise diagnosis of FMD in mithun (Fig. 26).

Clinical Diagnosis

In mithun, the clinical signs of FMD are clearly evident during disease outbreak and can range from mild or inapparent to severe. Tentative diagnosis of FMD in adult mithun is done based on presence of high fever (up to 106 °C), anorexia, presence of vesicles on muzzle, dental pad, buccal and nasal mucous membranes, smacking of lips, grinding of teeth, hypersalivation and drooling of ropy saliva from the mouth, vesicles between the hooves, around coronary band and heel bulbs, lameness, stamping or kicking of the feet. In most cases, vesicles rupture after 24 hours leaving ulcers or erosions. In mithun calf, FMD is suspected in case of sudden death without clinical signs.

Laboratory Diagnosis

The sample of choice is tissue (1 g) from unruptured or recently ruptured vesicle or epithelial sample which is collected and transported in a transport medium (pH of 7.2-7.6) maintaining the cold chain. The laboratory diagnosis of FMD is carried out on the basis of:

i. Virus detection

The OIE recommended routine methods for the detection of FMD virus include virus isolation, antigen detection ELISA (Ag-ELISA) and nucleic acid recognition (NAR).

a. Virus isolation

In vitro method for the detection of live FMD virus in clinical samples is virus isolation. Primary bovine thyroid cells (BTY) or primary pig, calf or lamb kidney cells, baby hamster kidney fibroblasts (BHK-21) or pig kidney (IB-RS-2) cells or fetal goat tongue cells (ZZR 127102) are commonly used for FMD virus isolation.

b. Antigen detection ELISA (Ag-ELISA)

This method is used for antigen detection and virus serotyping. Ag-ELISA is considered to be more sensitive than the complement fixation test (CFT).

c. RT-PCR (Reverse Transcription-Polymerase Chain Reaction)

RT-PCR is a rapid and sensitive technique that recognizes nucleic acids of the virus. It allows rapid detection of FMD virus genome from diverse group of biological specimens such as nasal swabs, vesicular epithelium, milk, serum, semen, etc. A variety of RT-PCR procedures have been developed for the detection of FMD virus genome: conventional RT-PCR, RT-PCR ELISA, nested RT-PCR, real-time RT-PCR, portable real-time RT-PCR, RT-insulated isothermal PCR (RT-iiPCR), RT-ddPCR (droplet digital PCR), RT-PCR microarray and automated RT-PCR. In general, RT-PCR is mostly performed to detect FMD virus in ELISA negative samples.

ii. Antibody detection

a. Detection of antibodies against the structural proteins of FMD virus

Antibodies against the structural proteins of FMDV are detected by virus neutralization test (VNT), liquid-phase blocking ELISA (LPBE) and solid phase competitive ELISA (SPCE) as recommended by the OIE. VNT is commonly used as a confirmatory test for sera found positive by ELISA. However, VNT is labour intensive, requires sensitive cell lines, live FMD virus and containment laboratory facility. The advantages of ELISA over VNT are that the test is rapid, can use inactivated antigens and requires smaller volumes of sera. LPBE based antibody detection system is quicker, more reproducible, less variable and the result correlates well with VNT. If the disease is reported late, liquid-phase blocking ELISA is usually used for diagnosis. The SPCE has higher specificity than LPBE.

b. Detection of antibodies against the non-structural proteins of FMD virus

Diagnosis of FMDV by detecting the antibodies against structural proteins is a useful technique but only in mithuns which have no history of vaccination (as the vaccine elicits antibodies against the structural proteins only). The natural infection of FMD

triggers formation of antibodies against both the structural and non-structural proteins. Hence, an ELISA that evaluates antibodies against non-structural proteins is useful for differentiating infected from vaccinated animals (DIVA). Non-structural protein serology is carried out by using commercially available kits.

c. Mucosal antibody detection

The excretory and secretory antibody IgA test has the potential to detect persistently infected animals. Based on oropharyngeal IgA responses, it is well known that administration of FMD vaccine does not elicit IgA antibody level in saliva.

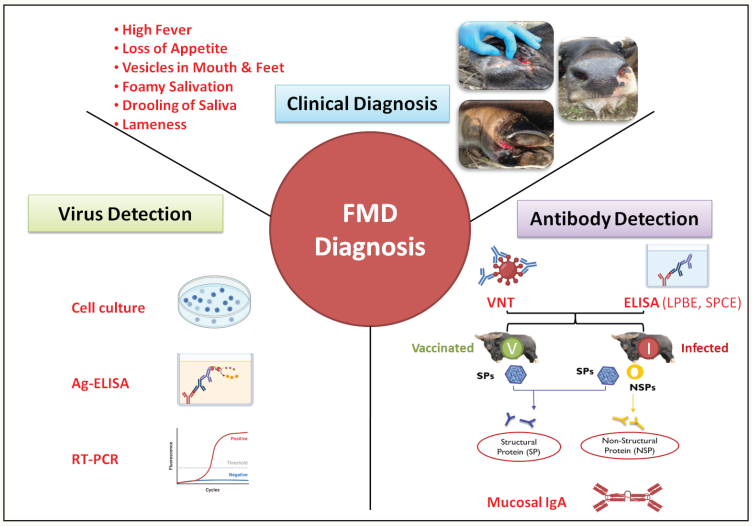

Fig. 26: Different methods used in the diagnosis of FMD

QUICK SUMMARY

- In mithun, early diagnosis of FMD is of utmost importance to check its rapid spread.
- Tentative diagnosis of FMD is based on clinical signs such as high fever (up to 106 °C), vesicles in mouth and feet, drooling of ropy saliva from the mouth, lameness, etc.
- The sample of choice for laboratory diagnosis of FMD is tissue or fluid from vesicles.
- Ag-ELISA and RT-PCR are frequently used laboratory techniques for diagnosis of FMD.

9 SUPPORTIVE TREATMENT FOR FMD IN MITHUN

The free-ranging mithun is constantly exposed to various infectious diseases in the forest as it is quite difficult to implement disease control measures in mithun because of their habitation. Although there exists no specific treatment for FMD in mithun, vesicles and erosions in tongue, nostrils, muzzle and inter-digital spaces of feet should be treated to check the secondary infection/ complication and augment the immune system to recover. In most instances of FMD outbreak in mithun, treatment of infected mithuns is not easy due to difficulty in restraining them in the forests, thus, increasing the number of mortalities. In forest, mithuns suffering from FMD continue to remain unattended and untreated for a number of days. Consequently, they cannot eat and move, become weak and ultimately, die due to starvation.

It is well known that there is no real cure for FMD infected mithuns, however as the disease progresses, infected mithuns should be separated from other animals and supportive or symptomatic treatment can be provided to reduce the complications of secondary infection and alleviate the condition. Moreover, in FMD endemic regions, vaccination around the areas of outbreaks might be used to limit the spread of the infection.

In mithun, the supportive treatment should be given both locally and generally/ systemically.

Localized Treatment

This refers to local treatment of wounds in the mouth and on the feet of mithun. It includes local or topical application of standard antiseptics (solution), soothing substances (paste, gel), wound healing agents (ointment, powder) and maggoticidals (maggot-killing) and fly repellents (spray) (Fig. 27).

a. **Rinsing and Cleaning:** The ruputured and ulcerated vesicles in mouth, tongue, nostrils and inter-digital spaces of hooves are thoroughly washed and cleaned with one of the following antiseptic solutions:

- **1:5000 Potassium permanganate ($KMnO_4$)** (Potassium permanganate I.P. crystal 10 g or 20 g)

RULE OF THUMB: In layman's terms, a 1:5000 therapeutic solution of potassium permanganate is made by dissolving a pinch of crystals (Fig. 28a) in water in such a way that the bottom of container or bucket can be easily viewed through the solution (see-through solution) (Fig. 28b). The ideal potassium permanganate solution with antiseptic property should be pink colored instead of dark violet/purple (Fig. 28c). Each time this solution is prepared freshly.

Potassium permanganate crystals and concentrated solution are caustic and can burn the skin of mithun. Even fairly dilute solutions can irritate skin and repeated use may cause burns. Twice daily baths for 3-5 days are helpful to dry out the blisters.

(a) **(b)**

Fig. 27 Localized treatment of FMD-infected mithun

(a) Crystals of $KMnO_4$ **(b)** Antiseptic solution ☑ CORRECT **(c)** Concentrated solution ☒ WRONG

Fig. 28 Preparation of therapeutic solution of potassium permanganate

- **5 % Povidone-iodine** (Betadine)
- **2 % Alum**
- **0.5-1 % Sodium bicarbonate** (Baking soda)
- **Normal saline solution**
- **1 % Citric acid**
- **1 % Methylene blue**
- **Juice of sour fruits such as lemon, starfruit** for washing oral lesions

b. **Wound Dressing and Bandaging:** After cleaning the wound, dry it with cotton wool or clean towel or cotton cloth and apply antibiotic cream/ointment **(Betnovate-GM, Soframycin)** or dusting powder **(Neosporin, Negasunt, Nebasulf, GotBac)** or wound healing spray **(Topicure, Exoheal)** over the wound. At last, apply maggoticidal and fly repellent spray **(D'Mag, Lorexane)** or ointment **(Himax)** over the wound to keep the flies at bay.

If fly repellent is not available, bandage all the foot lesions for the prevention of flies and subsequent development of maggot wounds. Based on the nature of wound, bandages can be left in place from few days to several weeks. However, it is always advisable to continue dressing of wound on alternate day until healing.

If the bandage gets wet or a bad odor is felt from the wound, the veterinarian should be immediately contacted for evaluation. A foul smell strongly suggests presence of fly maggots in the wound.

A 5 % boroglycerine lotion/paste or 1 % chlorhexidine gluconate **(Hexigel)** is topically applied twice daily over the mouth erosions for early healing.

Generalized Treatment

This refers to systematic administration of antimicrobials (long-acting), anti-inflammatory agents/antipyretics, antihistaminics, multivitamin including vitamin A & E and appetizers/liver tonic treatment against further bacterial infection (Fig. 29 & 30). In case of maggot wounds, injectable ivermectin is also administered in mithun.

a. **Antimicrobials (long-acting):** Restraining mithuns in the forest is the most difficult component of their treatment. Hence, long-acting broad spectrum

antimicrobials are commonly used in mithun as they offer long acting antimicrobial activity and reduce the number of injections in free-ranging mithuns. The second application should be administered only after 3 days, if required.

S. No.	Generic name	Trade name	Dose	Route
1.	Enrofloxacin 10 %	Flobac SA Fortivir Floxidin LA	7.5 ml/100 kg (7.5 mg/kg)	IM, SC, IV* slow
2.	Oxytetracycline 20 %	Oxynex LA Terramycin LA Oxtetracycline LA	10 ml/100 kg (20 mg/kg)	Deep IM

*IM = Intramuscularly; SC = Subcutaneously; IV = Intravenously

Note that the administered dose should not exceed 15 ml for enrofloxacin and 20 ml for oxytetracycline at a single site.

b. Nonsteroidal anti-inflammatories & antipyretics: These fast-acting drugs are administered to mithun to control inflammation, alleviate pain, combat fever and restore mobility.

S.No.	Generic name	Trade name	Dose	Route	Duration
1.	Meloxicam & Paracetamol	Melonex Plus Inflavet Zobid-MP	4 ml/100 kg/day	IM	3-5 days
2.	Flunixin meglumine	Megludyne Flunimeg Finadyne	4 ml/100 kg/day	IM IV slow	3-5 days
3.	Nimusulide 10 %	Nimovet	4 ml/100 kg/day	IM	3-5 days
4.	Phenylbutazone & Sodium salicylate	Artizone-S	Adult mithun: 20-30 ml/day on first 2 days, 10-15 ml/day afterwards	IM IV slow	3-5 days

c. Antihistaminics: These drugs have drying effects on excessive mucous secretion and are used to relieve symptoms of stomatitis (sore lip/mouth), runny nose, drooling of saliva from mouth and lameness.

S.No.	Generic name	Trade name	Dose	Route	Duration
1.	Pheniramine maleate	Avilin VET	2.5 ml/100 kg *or* 1 bolus/350 kg*	IM *or* Oral	2 times daily for 3-5 days
2.	Chlorpheniramine maleate	Cadistin Anistamin CPM	1 ml/100 kg/day	IM	

*1 bolus = 250 mg

d. Multivitamins including vitamin A & E and liver tonics: These drugs are given to treat debility, general weakness and inappetence/ anorexia during recovery period. Vitamin A and E are used to boost immunity and regeneration & growth of oral epithelium.

S.No.	Generic name	Trade name	Dose	Route	Duration
1.	B-complex & Liver extract	Belamyl	Adult: 5-10 ml/day qod Young: 1-2 ml/day qod*	IM	3-5 days
2.	B-complex	Tribivet Conciplex	5-10 ml/350-400 kg od/bd**	IM	3-5 days
3.	Vitamin A & E	Intavita-H	10 ml/350-400 kg/day qod	IM	3-5 days

*qod = alternate days; **od = once daily; bd = twice daily

Fig. 29: Frequently used drugs in the treatment of FMD in mithun

Fig. 30: Generalized treatment of FMD infected mithun

Management of Maggot Wound in Free-Ranging Mithuns

The free-ranging mithuns suffering from FMD are highly vulnerable to different flies in the moist and humid interiors of the rain forests. These flies usually infest mithun that has an open wound in the mouth/nasal cavity/feet after the rupture of FMD vesicles. If the wound is left unattended in the forest, the smell of blood/pus attracts the flies, they lay eggs on the wound and up to 200 maggots (slimy white worm-like) emerge per day and start feeding on the tissues of mithun. If still the maggot wound remains open, it further attracts secondary flies which again lay eggs and mithun may be dead in 2 weeks due to being eaten alive by flies and mixed bacterial infections. The treatment of maggot wound is quite simple and the various steps are:

- A tiny hole on the skin surface with a characteristic stinking smell (rotting flesh smell) is often suspected to be a maggot wound.
- The maggots are removed by keeping the cotton gauze dipped in turpentine or eucalyptus oil for 2-4 minutes in the wound pocket and as the maggots pop out to the surface, they are removed with blunt forceps or tweezers.
- If the wound is deep seated and only a tiny hole is visible outside, then 5-10 ml turpentine oil is taken into a plastic syringe (without needle), pushed into the hole and allowed to act over the next 6-8 hours. A large chunk of maggots begins to come out of the wound as the oil exerts its effect.

- The wound area is cleaned with antiseptic solution such as 5 % povidone-iodine, tincture of iodine, etc.
- The dusting powder (Neosporin, Negasunt, etc.) is put into and over the wound.
- Next step includes filling up the hole or wound with wound healing and maggoticidal ointment (Lorexane). Wherever feasible, the wound is made airtight by stuffing gauze into the wound and covering with a bandage. The dressing of wound at least on alternate day is necessary until healing.
- At the end, fly repellent spray (Topicure, D'Mag) or ointment (Himax) is liberally applied over the wound to prevent flies from sitting on the wound and re-infesting it further with maggots.
- In case only superficial maggots are removed from the wound, a single dose of 1 % ivermectin **(Neomec, Hitek)** is usually administered subcutaneously at the rate of **1 ml per 50 kg** body weight.
- Based on the severity of wound, long-acting injection of a broad-spectrum antibiotic can also be given.

Ethnoveterinary Remedies for FMD

Although use of ethnoveterinary remedies for FMD is not a prevalent practice in mithun, few preparations found useful in cattle may be used in mithun.

1. The **paste of finger millet flour and honey** can be applied to the mouth lesions. If used regularly, oral lesions often heal in a period of 4-5 days and affected animals resume eating slowly from third day onward.
2. Oral ethnoveterinary formulation containing cumin seeds, fenugreek seeds, black pepper, turmeric, garlic, coconut and jaggery. Each time this formulation is prepared freshly. The preparation of a single dose requires:

a. **Cumin seeds (jeera)** 10 gram

b. **Fenugreek seeds (methi)** 10 gram

c. **Black pepper (kaalee mirch/jaluk)** 10 gram

d. **Turmeric (haldi)** (rhizome or powder) 10 gram

e. **Garlic (chiimerie)** 4 pearls

f. **Coconut (narikol)** (grated) 1 full

g. **Jaggery (gur)** 120 gram

Method of Preparation:

- Soak cumin seeds, fenugreek seeds and black pepper in clean water for 20-30 minutes.
- Blend the soaked mixture thoroughly.
- Add turmeric, garlic and jaggery and blend again.
- Add grated coconut to the paste and administer to the infected mithun.

Method of Administration:

- Divide the single dose into small parts.
- Apply slowly and gently over the lesions on tongue, gums and palate.
- Repeat the administration to complete the dose. Administer the preparation thrice a day.
- Continue application for 3-5 days.

QUICK SUMMARY

- There is no specific treatment for FMD in mithun, however as the disease progresses, supportive or symptomatic treatment should be provided to reduce the complications.
- In endemic regions, vaccination around the areas of outbreaks might be used to limit the spread of FMD.
- Long-acting broad spectrum antimicrobials (Enrofloxacin, Oxytetracycline) are commonly used in free-ranging mithuns.
- The management of maggot wounds in free-ranging mithuns suffering from FMD is extremely important and if left unattended, mithun may be dead in 2 weeks due to being eaten alive by maggots and mixed bacterial infections.

10 PREVENTION AND CONTROL OF FMD IN MITHUN

Prevention is better than cure looks very relevant in case of FMD in mithun. Informed mithun owner or farmer with ability to recognize the essential signs of FMD, is the most important resource in the prevention of FMD. Spreading awareness among mithun farmers about better vaccination coverage against FMD in mithun is one of the useful tools in mithun conservation. It is also imperative to train atleast two farmers from each registered mithun society on proper landmarking and administration of vaccine by subcutaneous and intramuscular routes. In present times, ICAR-National Research Centre on Mithun, Nagaland has conducted a large number of outreach programmes in different mithun rearing states to raise awareness about the prevention and control of FMD in mithun (Fig. 31 a-d).

(a)

(b)

(c)

(d)

Fig. 31: Educating mithun farmers about FMD at (a) Konsakhul village, Kangpokpi, Manipur (b) Mirem village, East Siang, Arunachal Pradesh (c) Mawai village, Kamjong, Manipur and (d) Kangkum village, Kamjong, Manipur

Strategies for Prevention of FMD in Mithun

1. Medical Prophylaxis

- **Preventive vaccination**

Vaccination is the most effective strategy to prevent, control or eradicate the disease. From mithun welfare perspective, preventive mass vaccination is regarded as the best option to prevent FMD outbreak. Inactivated virus vaccines protect mithun from clinical illness for 4-6 months against the specific serotype(s) contained in the vaccine. The vaccination of free-ranging mithuns should be carried out regularly with administration of **first dose at 4 months of age**, followed by second dose at 2-4 weeks after first vaccination, then repeated once in 6 months interval preferably before monsoon season (during April-May). At present, the commonly used bovine vaccine against FMD in mithun is **'Raksha Trivalent'** (Fig. 32) which is given **twice yearly** at a dose of **3 ml by subcutaneous route**. It is mandatory to vaccinate all (100 %) the mithuns of a village at one time.

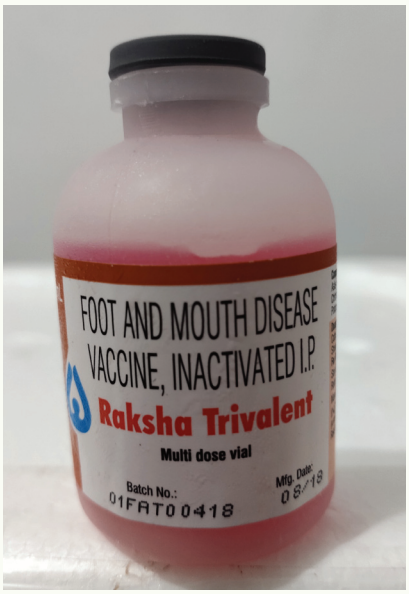

Fig. 32: Commonly used FMD vaccine in mithun 'Raksha Trivalent'

RULE OF THUMB: Vaccine should be administered only to healthy mithuns. If a vaccine is administered to an unhealthy mithun, it may fail to provide the required immunity against FMD. Ideally, debilitated and sick mithuns, recently calved mithun cows (up to 3-4 weeks after calving), mithuns in the last month of pregnancy, mithuns under stress and mithun calves until 4 months of age should not be vaccinated.

Apart from the sickness, other non-ideal conditions for vaccination are physiological stress, parasitism and adverse weather conditions. High worm load or tick infestation (parasitism) causes physiological stress to the mithun (Fig. 33). This stress may interfere with the desired response towards the vaccine in terms of immunity development. Therefore, if possible, all mithuns must be dewormed before FMD vaccination.

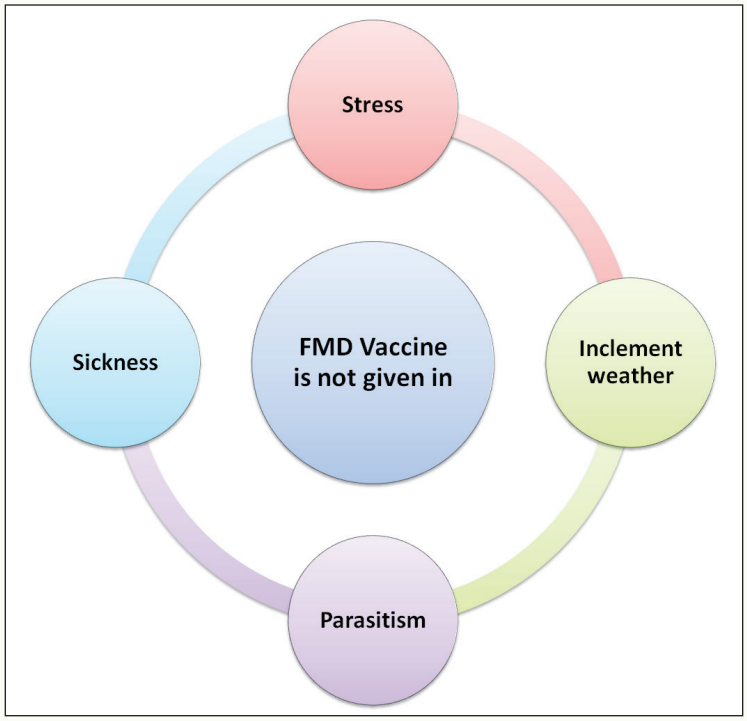

Fig. 33: Non-ideal conditions for FMD vaccination in mithun

Deworming of mithun with one of several broad spectrum anthelmintics is an effective preventive practice.

S.No.	Generic name	Trade name	Dose	Route
1.	Fenbendazole*	Panacur Vet Fentas Fenbezole	150 mg tablet/30 kg *or* 1.5 g bolus/300 kg	Oral
2.	Albendazole	Albomar Intalben Albonil	150 mg tablet/20 kg *or* 6 ml oral suspension/20 kg *or* 1.5 g bolus/200 kg	Oral
3.	Ivermectin	Hitek Neomec Trumectin	1 ml/50 kg (1 % injection) *or* 80 mg/400 kg (80 mg bolus) *or* 2.5 ml/10 kg (0.08 % solution)	Subcutaneous *or* Oral *or* Oral

*Safe for pregnant mithuns in any stage of gestation

Sanitary Prophylaxis

- **Restriction on transboundary animal movements**

The transmission of FMD from wildlife and domestic livestock to free-ranging mithun can be controlled by separating mithun from other species with fences made of barbed wire or closely placed cactus plants or bamboos (bio-fencing). The fencing is done in the periphery of community land used to rear mithuns in the forests. This will further check transboundary movement of animals and interspecies mingling. At present, ICAR-National Research Centre on Mithun is making every effort to provide fencing inputs such as barbed wires and technical back-up to the mithun farmers by organizing input distribution programmes in villages (Fig 34 a & b).

(a)

(b)

Fig. 34 Input distribution programmes organized at (a) Haipi village, Kangpokpi, Manipur and (b) Kangkum village, Kamjong, Manipur

- **Strong surveillance program**

It is based on epidemiological and statistical principles and often identifies potential risk factors for infection. A strong surveillance program is needed for mithun to determine the endemic rates of occurrence of FMD, investigate FMD outbreaks and assess the effectiveness of prevention & control measures.

- **Quarantine of arriving mithuns**

The newly purchased mithuns from outside the village should be kept in strict quarantine (isolation) for a minimum period of 4 weeks before mixing with other mithuns of the village and observed for signs of any disease. The quarantine shed should be constructed at the entrance of a village.

- **Purchase of mithuns from low-risk areas**

To the extent possible, mithuns should preferably be purchased from a place where FMD has not been recorded for a period of ≥ 6 months. Furthermore, new mithuns should not be purchased and brought to the village until 6 months after FMD outbreak in village. In case of semi-intensively reared mithuns, fodder should not be procured from high-risk FMD areas.

- **Prohibition of unvaccinated mithuns**

Unvaccinated mithuns should not be allowed to mithun melas (fairs). Only vaccinated mithuns should be brought from the forest to the village for fairs and that too only 2-3 weeks after vaccination.

- **Foot bath or truck bath at entry point**

A foot bath or foot dip or truck bath is a front line of protection against transfer of infection and may be made at the entrance of the village or mithun farm. Lime powder or bleaching powder or equal proportion of the two may be used in foot baths.

- **Adoption of semi-intensive system of mithun rearing**

Mithun is mainly reared under free-range forest ecosystem without scientific supervision of health, nutrition and reproduction. However, in the present scenario, shifting to scientific mithun farming i.e. semi-intensive system is utmost important. It is an alternative system of mithun rearing, where mithuns are allowed to freely

(a) (b)

Fig. 35: Semi-intensive units established at (a) Machi village, Tengnoupal, Manipur and (b) Nzau village, Tening (Peren), Nagaland

roam in the forest during daytime and brought back to the village and offered a shed during night time. ICAR-National Research Centre on Mithun is relentlessly working to provide technical backstopping and construction materials for the establishment of semi-intensive units in the field conditions (Fig. 35 a & b). It is advocated that semi-intensive mithun farming shall allow farmers to monitor health of mithuns, restrain them with ease for vaccination and thus, prevent FMD outbreak in mithun.

Strategies for Control of FMD in Mithun

- **Rapid disease reporting**

FMD is a notifiable disease, therefore, intensified surveillance and rapid reporting of suspected or confirmed cases are essential to control an FMD outbreak and locate the source of infection.

- **Personal hygiene of mithun handlers**

During FMD outbreaks, healthy mithuns should be attended first and then the infected ones. After attending the sick animals, mithun owner or handler should wash himself and his clothes with 4% sodium carbonate solution so as to prevent mechanical transmission of FMD. The people who have come into contact with the diseased mithun must avoid contact with susceptible animals for a period of time.

- **Isolation of sick mithuns and restriction on their movements**

During FMD outbreaks, immediately after the detection of clinical signs, infected mithuns should be restrained, isolated and confined in a semi-intensive unit or other housing structure/shed. This might be helpful to restrict mithun movements and check further spread of FMD. Furthermore, diseased mithuns should not be allowed to graze in community grazing pasture. To the extent possible, the affected mithuns should not be allowed to drink water from ponds, streams and rivers.

- **Prevention of suckling of infected dams**

Mithun calves should not be allowed to suckle infected dams as virus transmission to calves is likely via ingestion of contaminated milk.

- **Prompt treatment of infected mithuns**

There is no real cure for FMD infected mithuns, however as the disease progresses, localized and generalized supportive or symptomatic treatment can be provided to infected mithuns to reduce the complications of secondary infections and alleviate the condition.

- **Emergency vaccination**

It is not a routine practice in case of FMD outbreaks in mithun but might be useful in severe cases. Generally, it is applied as an immediate response to an outbreak of FMD. It is a part of a control strategy or contingency plan where the susceptible mithun population around and within the FMD outbreak area **(5-10 km)** is vaccinated **(Ring Vaccination** or **Dampening Down Vaccination)**. This is done to prevent outward spread of FMD and to boost existing immunity of the animals.

- **Cleaning and disinfection**

In semi-intensive mithun farms and units, floors, premises and all infected materials such as implements, etc. should be disinfected by using sodium carbonate (4 %), sodium hydroxide (2 %) and citric acid (0.2 %). Lime powder should be sprinkled around the mithun sheds or shelters. Scavengers and rodents should be prevented or killed to prevent mechanical dissemination of virus.

- **Effective disposal of carcasses**

Infected carcasses, contaminated animal products (meat, milk) and manure must be disposed of via burial or burning (incineration). In general, burial is the preferred method and involves removing soil from the ground to a depth of 3-4 feet, depositing the carcass into the excavated area/trench, and then covering the carcass with the soil. The burial site should be away from the water bodies. Prompt burial prevents flies and scavengers and thus, checks mechanical spread of FMD. Open or uncontrolled burning is used to thermally destroy animal carcasses and associated materials but it is quite expensive method.

QUICK SUMMARY

- Vaccination is the most effective strategy to prevent the outbreaks of FMD in mithun. The first dose is given at 4 months of age, followed by second dose at 2-4 weeks, then repeated once in 6 months i.e. twice yearly.
- Vaccine is administered only to healthy mithuns and all mithuns must be dewormed before FMD vaccination with broad spectrum anthelmintic.
- Barbed fencing or bio-fencing of the forests might prevent transmission of FMD from wildlife and domestic livestock to free-ranging mithun by checking transboundary movement and interspecies mingling.
- Rapid disease reporting, isolation and prompt treatment of sick mithuns and effective disposal of carcasses often serve as the useful tools in the control of FMD in mithun.

11 CONSTRAINTS IN VACCINATION AGAINST FMD IN MITHUN

Vaccination is intended to prevent and control the occurrence of FMD and reduce the transmission of the pathogenic FMD virus in mithun. Ideally, vaccines should induce immunity against the circulating serotype of FMD virus. Being a browser, mithun often travels long distances in the dense hilly forests in search of fodder and drinking water. Therefore, due to geographical constraints, it's a herculean and impractical task to get access to the dense forests, restrain free-ranging mithuns and bring them to the villages for regular vaccination against FMD. It goes without saying that mithun inhabits the hilly forests and this hinders the vaccination of major part of mithun population against FMD, which is undoubtedly a matter of grave concern to mithun farmers. However, vaccination in mithun at regular intervals is feasible by rearing mithun under semi-intensive system, where mithun is allowed to freely browse in the forest during daytime and offered a shed equipped with drinking water supply to stay during night time. At present, it is advocated to adopt semi-intensive mithun farming and prevent the outbreak of FMD in mithun.

Generally, the practice of vaccination in mithun is not followed by the majority of farmers due to their negligence, ignorance and superstitions about vaccination. mithun is mainly reared for organic meat in northeast India and the mithun farmers believe that vaccination degrades the quality of nutritious meat. The farmers strongly believe that vaccination in mithun leads to persistent high fever for few days and abortion in pregnant animals.

Moreover, the rural farmers remain full-time actively engaged in agricultural activities for livelihood and are usually unwilling to catch free-ranging mithuns from the forest area and take them to vaccination centres. Even if they are convinced, they demand monetary compensation amounting from Rs. 400 to 500 per mithun in exchange for their labor to catch mithun from the dense forest area.

The non-inclusion of mithun in foot and mouth disease control programme (FMD-CP) of Government of India further exacerbated the situation of FMD vaccination in mithun. Like cattle and buffalo, good veterinary services which allow rapid diagnosis and implementation of FMD control measures are lacking in the context of free-ranging mithun in northeast India. Furthermore, in many instances, unskilled farmers try to vaccinate mithun on their own without the help of veterinary professional and end up in delivery of FMD vaccine by intrasmuscular route instead of effective subcutaneous route.

QUICK SUMMARY

- Mithun inhabits dense forests and this geographical constraint hinders the vaccination of major part of mithun population against FMD, which is presently a matter of grave concern.
- Regular vaccination in mithun might be feasible by adopting semi-intensive rearing system, where mithun is allowed to browse in the forest during daytime and offered a shelter during night time.
- Vaccination in mithun is not practiced by the majority of farmers due to their negligence, ignorance and superstitions about vaccination.
- Inclusion of mithun in foot and mouth disease control programme (FMD-CP) is urgently required for implementation of FMD control measures in free-ranging mithuns.

REFERENCES

Barman, N. N., Sarma, D. K., Das, S., and Patgiri, G. P. (1999). Foot-and-mouth disease in wild and semi-domesticated animals of the north-eastern states of India. *Indian Journal of Animal Sciences*, 69(10), 781-783.

Barnett, P., Garland, A. J. M., Kitching, R. P. and Schermbrucker, C. G. (2002) Aspects of emergency vaccination against foot-and-mouth disease. *Comparative Immunology, Microbiology and Infectious Diseases*, 25(5-6), 345-364.

Bauer, K. (1997). Foot-and-mouth disease as zoonosis. *Viral Zoonoses and Food of Animal Origin*, 95-97.

Biswal, J. K., Sanyal, A., Rodriguez, L. L., Subramaniam, S., Arzt, J., Sharma, G. K., ... and Misri, J. (2012). Foot-and-mouth disease: Global status and Indian perspective.

Borah, B., Deka, P., Sharma, K., Baro, S., Hazarika, A. K., Das, C., ... and Ltu, K. (2018). Isolation, identification and retrospective study of foot-and-mouth disease virus from affected mithun *(Bos frontalis)* in north-eastern India. *Transboundary and Emerging Diseases*, 65(1), e63-e69.

Drugs Vaccine and Equipment Unit (2013). *National Veterinary Drug Formulary, Department of Livestock, Ministry of Agriculture and Forests, Bhutan.*

Ethnoveterinary treatment for FMD oral lesions, *National Dairy Development Board*, https://www.youtube.com/watch?v=62yCAgzYf08&t=149s.

Foot and mouth disease control programme, http://dadfonline.gov.in/FMDCP/Index.aspx.

https://www.msdvetmanual.com/generalized-conditions/foot-and-mouth-disease/foot-and-mouth-disease-in-animals.

ICAR-DFMD (2016) *Annual Report, 2015-16, ICAR-Directorate on Foot and Mouth Disease, Mukteswar, Nainital, India.*

ICAR-DFMD (2017) *Annual Report, 2016-17, ICAR-Directorate on Foot and Mouth Disease, Mukteswar, Nainital-263138, Uttarakhand, India.*

ICAR-DFMD (2018) *Annual Report, 2017-18, ICAR-Directorate on Foot and Mouth Disease, Mukteswar, Nainital-263138, Uttarakhand, India.*

ICAR-DFMD (2019) *Annual Report, 2018-19, ICAR-Directorate on Foot and Mouth Disease, Mukteswar, Nainital-263138, Uttarakhand, India.*

ICAR-PDFMD (2015) *Annual Report, 2014-15, Project Directorate on Foot and Mouth Disease, Mukteswar.*

Joshi, V., Chamuah, J. K., Lalzampuia, H.,.... and Khan, M. H. (2021). Foot and mouth disease (FMD) in mithun. Extension folder, *ICAR-National Research Centre on Mithun, Nagaland. https://nrcmithun.icar.gov.in.*

Joshi, V., Biam, K. P., Chamuah, J. K., R, Vikram, and Khan, M. H. (2020). Status and prospects of mithun farming in northeast India. *CAU Farm Magazine (ISBN: 2279-0454)*, 10(1), 16-19.

Joshi, V., Biam, K. P., and Khan, M. H. (2021). Factors and solutions for declining mithun population in Nagaland and Manipur: A perspective. *Biotica Research Today*, 3(7), 620-623.

Kumar, A., Singh, V., Pongen, T., Hazarika, S. B., and Mitra, A (2017). Normal reference ranges of oxidative markers in mithun population and their alterations during the foot and mouth disease. *Indian Journal of Animal Sciences*, 87(9): 1087-89.

Miller, L.P., Miknis, R.A. and Flory, G.A. (2020) Carcass management guidelines-Effective disposal of animal carcasses and contaminated materials on small to medium-sized farms. *FAO Animal Production and Health Guidelines no. 23.* Rome, FAO. https://doi.org/10.4060/cb2464en.

Mondal, M. (2001). Physio-chemical properties of mithun milk. *Indian Journal of Animal Sciences*, 71, 1066-1068.

Mukherjee, S., Cai, Z., Mukherjee, A., Longkumer, I., Mech, M., Vupru, K., ... and Sahana, G. (2019). Whole genome sequence and de novo assembly revealed genomic architecture of Indian mithun *(Bos frontalis)*. *BMC Genomics*, 20(1), 1-12.

Pal, D. T., Dhali, A., Mondal, S. K., Rajkhowa, C., and Bujarbaruah, K. M. (2008). Water intake and utilization in mithun *(Bos frontalis)*: effect of environmental temperature, rearing system and concentrate feed supplement. *Journal of Mountain Science*, 5(2), 178-188.

Paton, D. J., Gubbins, S., and King, D. P. (2018). Understanding the transmission of foot-and-mouth disease virus at different scales. *Current Opinion in Virology*, 28, 85-91.

PDFMD (2009) *Annual Report, 2008-09, Project Directorate on Foot and Mouth Disease, Mukteswar.*

PDFMD (2010) *Annual Report, 2009-10, Project Directorate on Foot and Mouth Disease, Mukteswar.*

PDFMD (2011) *Annual Report, 2010-11, Project Directorate on Foot and Mouth Disease, Mukteswar.*

PDFMD (2012) *Annual Report, 2011-12, Project Directorate on Foot and Mouth Disease, Mukteswar.*

PDFMD (2013) *Annual Report, 2012-13, Project Directorate on Foot and Mouth Disease, Mukteswar.*

PDFMD (2014) *Annual Report, 2013-14, Project Directorate on Foot and Mouth Disease, Mukteswar.*

Perumal, P., Khate, K., and Rajkhowa, C. (2013). Effect of foot and mouth disease vaccination on seminal and biochemical profiles of mithun *(Bos frontalis)* semen. *Asian Pacific Journal of Reproduction*, 2(3), 178-184.

Perumal, P. (2018). Effect of foot and mouth disease vaccination on seminal antioxidant profiles of mithun *(Bos frontalis)*. *Asian Pacific Journal of Reproduction*, 7(4), 178.

Prakash, B., Dhali, A., Rathore, S. S., Das, K. C., Walling, I., Vupru, K., ... and Rajkhowa, C. (2009). Chemical composition and nutritional evaluation of various foliages consumed by mithun *(Bos frontalis)*. *Animal Feed Science and Technology*, 150(3-4), 223-229.

Rajkhowa, S., Rajkhowa, C. and Bujarbaruah, K.M. (2008). Diseases of mithun *(Bos frontalis). National Research Centre on Mithun (ICAR), Jharnapani, Nagaland*, 68-72.

Rajkhowa, S., Rajkhowa, C., and Bujarbaruah, K. M. (2003). Diseases of mithun *(Bos frontalis)*-a review. *Veterinary Bulletin*, 73(4).

Ranjan, R., Biswal, J. K., Sharma, G. K., and Pattnaik, B. (2016). A review on foot-and-mouth disease: pathology, diagnosis and its management. *Indian Journal of Veterinary Pathology*, 40, 105-115.

Raveendra, H., Gomes, A. R., Giridhar, P., Venkatesh, M. D., and Renukaprasad, C. (2011). A note on FMD in mithun *(Bos frontalis)* and black buck *(Antelope cervicapra)*. *Zoos' Print*, 26(6).

Rout, M., Subramaniam, S., Mohapatra, J. K., Sanyal, A., Dash, B. B., and Pattnaik, B. (2017). Phylogenetic characterization of foot-and-mouth disease virus recovered from mithuns and yaks in India. *Indian Journal of Animal Research*, 51(6).

Rout, M., Subramaniam, S., Sanyal, A., Dash, B. B., Sharma, K., Misri, J., and Pattnaik, B. Foot and mouth disease in sheep, goats, semi-domesticated and wild animals.

Sarma, D. K. (2005). Foot-and-mouth disease in the north eastern states of India: Review on the status of FMD outbreak and control. *The Blue Cross Book-24 (ISSN 0972-4680)*, 15-21.

World Organization for Animal Health (2019). *Terrestrial Animal Health Code.*

हर कदम, हर डगर
किसानों का हमसफर
भारतीय कृषि अनुसंधान परिषद

Agrisearch with a human touch

भाकृअनुप
ICAR

ICAR-NATIONAL RESEARCH CENTRE ON MITHUN
MEDZIPHEMA, NAGALAND - 797 106
Website: www. nrcmithun.icar.gov.in
Nrc On Mithun NRCMITHUN Nrc Mithun

I.C.A.R. N.R.C. MITHUN-NAGALAND